STUDY OF LIGATURE MARK IN CASES OF HANGING

by

Dr. K. ASHWINI NARAYAN

Dissertation submitted to
Rajiv Gandhi University of Health Sciences, Bangalore, Karnataka

In partial fulfillment of the University Regulations for the award of

M.D
In

FORENSIC MEDICINE

Under the Guidance of
Dr. Y.P. GIRISH CHANDRA
Associate Professor, Dept. of Forensic Medicine



Department of Forensic Medicine
M.S.Ramaiah Medical College and Teaching Hospital
Bangalore

2003 – 2006

Create PDF files without this message by purchasing novaPDF printer (http://www.novapdf.com)

RAJIV GANDHI UNIVERSITY OF HEALTH SCIENCES

DECLARATION BY THE CANDIDATE

I hereby declare that this dissertation/thesis entitled **"STUDY OF LIGATURE MARK IN CASES OF HANGING"** is a bonafide and genuine research work carried out by me under the guidance of **Dr. Y.P. Girish Chandra, MD. Associate Professor**, Department of Forensic Medicine, and Co-Guide **Dr. S. Harish MD, DFM** Prof. And H.O.D. Dept. of Forensic Medicine, M.S.Ramaiah Medical College.

Date :
Place:

Dr. K. Ashwini Narayan

Create PDF files without this message by purchasing novaPDF printer (http://www.novapdf.com)

CERTIFICATE BY THE GUIDE

This is to certify that the dissertation entitled **"STUDY OF LIGATURE MARK IN CASES OF HANGING"** is a bonafide research work done by **Dr. K. Ashwini Narayan,** under my direct guidance and supervision in the Department of Forensic Medicine ,M. S. Ramaiah Medical College, Bangalore in partial fulfillment of the requirement for the degree of MD in Forensic Medicine.

Date:
Place:

Dr. Y.P. GIRISH CHANDRA
Associate Professor
Department of Forensic Medicine
M.S.Ramaiah Medical College.

Create PDF files without this message by purchasing novaPDF printer (http://www.novapdf.com)

CERTIFICATE BY THE CO- GUIDE

This is to certify that the dissertation entitled **"STUDY OF LIGATURE MARK IN CASES OF HANGING"** is a bonafide research work done by **Dr. K. Ashwini Narayan,** under the direct guidance of Dr. Y.P.Girish Chandra, Associate Professor., Department of Forensic Medicine, M.S.Ramaiah Medical College, Bangalore in partial fulfillment of the requirement for the degree of MD in Forensic Medicine.

Date:
Place:

Dr. S. HARISH
Professor and H.O.D.
Department of Forensic Medicine
M.S.Ramaiah Medical College.

Create PDF files without this message by purchasing novaPDF printer (http://www.novapdf.com)

ENDORSEMENT BY THE HOD, PRINCIPAL/HEAD OF THE INSTITUTION

This is to certify that the dissertation entitled **"STUDY OF LIGATURE MARK IN CASES OF HANGING"** is a bonafide research work done by **Dr. K. Ashwini Narayan**, under the guidance of **Dr. Y.P. Girish Chandra, Associate Professor**, Department of Forensic Medicine, M.S.Ramaiah Medical College, Bangalore.

Dr. S. HARISH
Prof. & H.O.D
Department of Forensic Medicine
M.S.Ramaiah Medical College

Date:
Place:

Dr. S. Kumar
Principal
M.S.Ramaiah Medical College

Date:
Place:

Create PDF files without this message by purchasing novaPDF printer (http://www.novapdf.com)

COPYRIGHT

DECLARATION BY THE CANDIDATE

I hereby declare that the Rajiv Gandhi University of Health Sciences, Karnataka shall have the rights to preserve, use and disseminate this dissertation / thesis in print or electronic format for academic / research purpose.

Date:
Place:

Dr. K. Ashwini Narayan

© Rajiv Gandhi University of Health Sciences, Karnataka

Create PDF files without this message by purchasing novaPDF printer (http://www.novapdf.com)

ACKNOWLEDGEMENT

I find inadequate to express my deep sense of gratitude to Dr.Y.P. GIRISH CHANDRA, my Guide and Associate Professor, for his devoted, kind and keen interest, encouragement, suggestions and able guidance throughout my study, amidst his busy schedule.

It has been a great privilege and pleasure to have worked under Prof. Dr.S.HARISH, my Co-Guide, Professor and Head of the department. The present work would not have been possible without his meticulous attention, sincere criticism and untiring help. I respectfully acknowledge him for his valuable guidance and support at every stage of my work.

I respectfully acknowledge the guidance and supervision accorded by my honorable teachers Dr.M.G.Shivaramu Associate Professor, Dr.J.Kiran Associate Professor, Dr.T.Padmanabha Assistant Professor, Dr.S.Praveen Lecturer, Dr.Rajesh.M Lecturer for their help and advice, who have added luster to this dissertation work. I also thank the staff of pathology department of M.S.Ramaiah Medical College for their services.

My sincere thanks to my colleagues, Dr.Avishek Kumar, Dr.Deepak D'Souza, Dr.Pradeep K Saralaya, Dr.Venkataraghava, Dr.Naveen Kumar, Dr.Sanjay Sukumar and Dr.Satish, Dr. Basappa and Dr. Vasudev for their co-operation. I express my gratitude to my parents and wife for their encouragement and support.

I am also obliged to the police personnel, mortuary staff and relatives of the deceased. Finally I bow my head to pay my obeisance to all the deceased for having been the source of data collection.

Dr.Ashwini Narayan

Create PDF files without this message by purchasing novaPDF printer (http://www.novapdf.com)

TABLE OF CONTENTS

SL. NO	CONTENTS	PAGE No
1.	INTRODUCTION	1-3
2.	AIMS AND OBJECTIVES	4
3.	REVIEW OF LITERATURE	5-30
4.	MATERIAL AND METHODS	31-33
5.	RESULTS AND DISCUSSION	34-60
6.	CONCLUSION AND SUMMARY	68-70
7.	LIMITATIONS AND RECOMMENDATIONS	71-72
8.	BIBLIOGRAPHY	73-77
9.	ANNEXURES	78-81

Create PDF files without this message by purchasing novaPDF printer (http://www.novapdf.com)

LIST OF TABLES

SL. NO	TABLES	PAGE NO.
1.	Age distribution in the study population	34
2.	Sex distribution in the study population	34
3.	Distribution in the study population according to the type of hanging (Suspension)	36
4.	Distribution in the study population according to the type of hanging (Ligature Mark)	36
5.	Distribution among the study population with respect to multiplicity of ligature mark	38
6.	Distribution among the study population according to the level of ligature mark	40
7.	Distribution in the study population according to the breadth of the ligature mark	42
8.	Distribution in the study population with respect to character of the ligature mark	44
9.	Distribution among the study population according to the Periligature injuries.	46
10.	Distribution in the study population with respect to the texture and parchmentisation of the ligature mark	48
11.	Distribution in the study population according to the colour of ligature mark	49

Create PDF files without this message by purchasing novaPDF printer (http://www.novapdf.com)

12.	Distribution in the study population with respect to the ligature material used	52
13.	Distribution in the study population according to the position of the knot	54
14.	Distribution in the study population according to the type of the knot	54
15.	Distribution in the study population based on effusion of blood into the deep tissues of the neck.	56
16.	Distribution in the study population with respect to the fracture of thyroid cartilage.	58
17.	Distribution in the study population with respect to the fracture of hyoid bone.	58

Create PDF files without this message by purchasing novaPDF printer (http://www.novapdf.com)

LIST OF FIGURES

SL. NO	FIGURES	Page No.
1.	Bar graph showing age distribution in the study population	35
2.	Pie chart showing sex distribution in the study population	35
3.	Pie chart showing distribution in the study population according to the type of hanging (suspension)	37
4.	Pie chart showing distribution in the study population according to the type of hanging (ligature mark)	37
5.	Bar graph showing distribution in the study population with respect to multiplicity of ligature mark. (number of ligature marks)	39
6.	Pie chart showing distribution in the study population according to the level of ligature mark	41
7.	Pie chart showing distribution in the study population according to the breadth of ligature mark	43
8, 9.	Pie chart showing distribution in the study population with respect to character of the ligature mark	45
10, 11	Pie chart showing distribution in the study population according to the periligature injuries.	47
12, 13	Pie chart showing distribution in the study population with respect to the texture and parchmentisation of the ligature mark	49

Create PDF files without this message by purchasing novaPDF printer (http://www.novapdf.com)

14.	Bar graph showing distribution in the study population according to the colour of the ligature mark	51
15.	Pie chart showing distribution in the study population with respect to the ligature materials used.	53
16.	Bar graph showing distribution in the study population according to the position of the knot	55
17.	Pie chart showing distribution in the study population according to the type of the knot	55
18.	Pie chart showing distribution in the study population based on effusion of blood into the deep tissues of the neck	57
19, 20	Pie charts showing distribution in the study population with respect to the fracture of thyroid cartilage and hyoid bone.	60

Create PDF files without this message by purchasing novaPDF printer (http://www.novapdf.com)

LIST OF PLATES

SL. NO	PLATES	Page No.
1.	Plate 1 : Photograph shows a case of "complete hanging" with a long drop.	61
2.	Plate 2 : Photograph shows a case of "partial hanging" (the deceased is in a kneeling position)	61
3.	Plate 3 : Photograph shows ligature mark only on the right side of the neck "Atypical ligature mark".	62
4.	Plate 4 : Photographs showing the ligature mark encircling the neck – narrow, grooved "Typical ligature mark".	62
5.	Plate 5 : Photograph showing a broad "Prominent and parchmentised mark" situated "Above the thyroid cartilage".	63
6.	Plate 6 : Photograph showing the ligature mark which is "Over riding" the thyroid cartilage	63
7.	Plate 7 : Photograph showing a "Faint ligature mark" situated "Below the level of thyroid cartilage".	64
8.	Plate 8 : Photograph showing "Periligature injury" – abrasion over the left angle of mandible.	64
9.	Plate 9 : Photograph showing "Multiple ligature marks" with ligature material in situ	65

Create PDF files without this message by purchasing novaPDF printer (http://www.novapdf.com)

10.	Plate 10 : Photograph showing “Extravasation” into the tissues over the right side of the neck in the case of long drop.	65
11.	Plate 11: Photograph showing “Fracture of right horn of Hyoid bone” in an elderly individual.	66
12.	Plate 12 : Photograph showing “Fracture of left cornua of the thyroid cartilage” in a case with multiple rows of ligature applied around the neck	66
13.	Photograph showing various types of ligature materials	67

Create PDF files without this message by purchasing novaPDF printer (http://www.novapdf.com)

INTRODUCTION

Violent asphyxial deaths is one of the most important cause for unnatural deaths amongst which hanging and strangulation are commonly encountered in day to day autopsy.

Hanging is that form of asphyxia, which is caused by suspension of the body by a ligature around the neck, the constricting force being the weight of the body. Deaths resulting from hanging show features amongst which the ligature mark in the neck is considered to be decisive.

The ligature mark is a pressure abrasion on the neck at the site of the ligature which appears as a groove. Character of the ligature mark depends on various factors like the nature of the ligature, body weight, length of time the body has remained suspended and the number of turns of the ligature round the neck. The course of the ligature mark depends on whether a fixed or running noose has been used.

In typical hanging, the ligature mark is situated above the level of thyroid cartilage between the larynx and the chin. It is directed obliquely upwards along the line of the mandible and reaches the mastoid processes behind the ears. It is sometimes absent at the back.

However variations in the ligature marks like faint/absent ligature mark, ligature mark artefacts (ex: ant bite marks) and other variables like a circular mark if the material is tied round the neck are encountered in day to day autopsies. Sometimes there may be double ligature marks. It may be due to slippage of the ligature .If the ligature is tied two or three times round the neck and then goes upto the knot, in addition to encircling marks, there is an inverted V shaped mark. This is confusing to

Create PDF files without this message by purchasing novaPDF printer (http://www.novapdf.com)

those not familiar with the combination of such marks who may associate the lower (horizontal) marks with ligature strangulation and the upper one with hanging. The ligature mark may be faint if a soft material is used or if the ligature is cut immediately after the hanging.

It is easy to diagnose hanging when one finds the classical features. However all features are seldom present together. The application of pressure on the neck often results in findings, which are quite variable. Thus the ligature mark around the victim's neck constitutes an extremely precious piece of evidence to arrive at a conclusion as to cause of death and manner of death. [1]

Create PDF files without this message by purchasing novaPDF printer (http://www.novapdf.com)

NEED FOR THE STUDY

In every human being death is inevitable. Some people for reasons not clearly understood choose to end their own lives. Motive for such deaths may be socioeconomic, psychological factors or health problems.

In the present day such deaths leaves puzzles like manner of death whether suicidal or homicidal. Commonest modes of committing suicides are by hanging or consumption of poison or drowning. In hanging the appreciation of external signs particularly ligature mark plays a vital role. Hence a proper observation and study of ligature mark which is the characteristic hallmark of hanging needs greater emphasis.

Apart from the typical ligature mark atypical ligature marks are also seen leading to lot of curiosity in the mind of autopsy surgeon during the day-to-day postmortem examination. Hence a prompt and sincere attempt is being made to study the correlation between the ligature mark and the material producing it along with the relation between external and internal features in the neck in cases of hanging.

Create PDF files without this message by purchasing novaPDF printer (http://www.novapdf.com)

AIMS & OBJECTIVES OF THE STUDY

1. To study the pattern of ligature marks.

2. To study the factors that contribute for the formation of ligature marks.

3. To correlate the ligature mark with the manner of death.

Thus Ligature mark/s, if can be the only finding to successfully distinguish a death resulting from hanging or otherwise, has been examined from medico-legal acumen.

Create PDF files without this message by purchasing novaPDF printer (http://www.novapdf.com)

REVIEW OF LITERATURE

Applied Anatomy of the Neck

The side of the neck is quadrilateral and divided into anterior and posterior triangles. **The anterior triangle of the neck**: This region includes the area from chin to sternum and the structures encountered are skin, superficial fascia, platysma, anterior jugular veins, submental lymph nodes, deep fascia above the hyoid bone, submandibular salivary gland, between the hyoid bone and cricoid cartilage, sternomastoid muscles, structures lying above hyoid bone are mylohyoid muscle overlapped by anterior belly of digastric muscle, submandibular salivary gland, mylohyoid nerve and vessels, submental branch of facial artery, hyoglossus muscle, stylohyoid muscle and hypoglossal nerve. Structures below hyoid bone: a) Infrahyoid muscles. b) Thyroid gland c) Larynx and trachea d) Oesophagus posteriorly. Further the anterior triangle of neck is subdivided into **a) Submental triangle b) Digastric triangle c) Carotid triangle.Posterior triangle of the neck:** Contains platysma, external jugular, posterior external jugular vein, part of supraclavicular, great auricular, lesser occipital nerve and occipital, transverse cervical, suprascapular arteries.

Back of the neck: Contains Ligamentum nuchae and muscles namely trapezius and latissimus dorsi, levator scapulae rhomboids, erector spinae occipital and deep cervical artery, third part of vertebral artery.[2]

Create PDF files without this message by purchasing novaPDF printer (http://www.novapdf.com)

Dissection techniques

For bloodless dissection of the neck first the thoracoabdominal contents and the brain is removed before proceeding to the neck dissection. A block 12 to 20cm high should be placed under the shoulders to allow the head to fall back thus the neck is extended. The skin is held with a tooth forceps and incision started from chin in the center and carried down till the pubis, subcutaneous dissection carried to the lower border of lower jaw, laterally on the sides of neck and clavicle. Deep cervical fascia is reflected from cervical muscles and strap muscles of the neck are exposed, inspected and reflected on each side. Thyroid gland and carotid sheath is freed by blunt dissection. Larynx, trachea, pharynx and oesophagus mobilized and pulled away from the prevertebral tissue by blunt dissection. The mouth is opened and the tip of tongue pushed upwards and backwards. The knife is inserted under the chin through the floor of the mouth cut along the sides of the mandible to the angle of the mandible dividing the neck muscles attached to the lower jaw. At the angle of mandible blade is turned inwards and tongue is pushed down under the mandibular arch, soft palate is cut to include uvula and tonsils with the tongue and the neck organs removed enmasse. Posteriorly the attachments are freed from the prevertebral muscles on the anterior surface of the cervical vertebra till the jugular notch and the great vessels are divided in the neck.[3]

Ligature Marks in hanging :

The description of the ligature mark includes its position, direction, continuous or interrupted, colour, depth, periligature injuries, ligature patterns areas of the neck involved and its relation to the local landmarks. When the loop is arranged

Create PDF files without this message by purchasing novaPDF printer (http://www.novapdf.com)

with fixed knot inverted V with its apex corresponding to the site of knot is produced, a fixed loop with a single knot in the midline at the back of the head produces mark on both the sides of neck and is directed obliquely upwards. Fixed loop with the knot in the region of one ear produces different ligature marks. On the side of the knot mark it is oblique and on the opposite side it is transverse. With a running noose a transverse mark may be produced with resemblance to strangulation. In partial hanging horizontal mark may be produced. Fixed loop with a single knot below the chin in the mid line produces a mark, which is seen on the back and both the sides of the neck and is directed obliquely towards the knot.

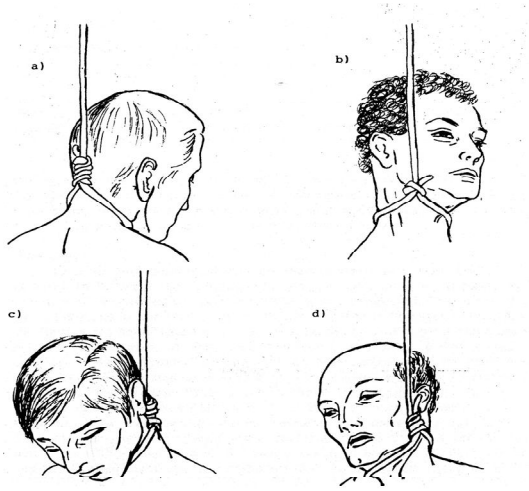

They stated that a broad ligature will produce only a superficial mark, if the ligature is passed twice round the neck, a double mark, one circular and the other oblique may be produced. Ligature may have one, two or more layers. Heavier the body and greater the time of suspension, more marked is the ligature impression .The mode of application of the ligature and the position of the knot, level at which the loop lies is important to distinguish between hanging and strangulation. The level of the ligature mark at or below the thyroid cartilage used as a criteria for distinguishing the

Create PDF files without this message by purchasing novaPDF printer (http://www.novapdf.com)

above. In hanging, internal injuries are remarkably infrequent and when present suggest that some violence has occurred such as from a drop. In addition to soft tissue injuries, which are infrequent, fractures may occur in both larynx and hyoid. The frequency with which these occur varies considerably in different series. In the authors own study, fractures of the superior horn of the thyroid cartilage are approximately equal to the fractures of the greater horn of the hyoid.[4]

He quoted that when the point of suspension is over the centre of the occiput, it is called typical hanging & point of suspension anywhere around the neck is atypical hanging. Usage of a soft ligature and if the body be cut down from the ligature immediately after death, there may be no mark. Again the intervention of a thick and long beard or clothes may lead to formation of a slight mark. Mark may be found on or below the thyroid cartilage in case of partial suspension. It may be circular if the ligature is first placed at the nape of the neck and then its two ends are brought horizontally forward and crossed, and carried upward to the point of suspension from behind the angle of the lower jaw on each side. The mark will be both circular and oblique if ligature is passed around the neck more than once varies according to the nature of material used as a ligature and period of suspension after death. Presence of abrasions with hemorrhage around ligature are strongly suggestive of antemortem hanging. The mark is well defined narrow and deep if a firm string is used. Mark is a groove or furrow and the base is pale, hard, leathery and parchment like and the margins red and congested and deepest near the knot. The mark is superficial and broad, if a cloth or a soft rope is used. Wide band of cloth when used as a ligature on bare skin may cause a narrow ligature mark due to tension lines in the stretched cloth.

Create PDF files without this message by purchasing novaPDF printer (http://www.novapdf.com)

Gordon et al, suggested presence of tissue reaction, indicate antemortem hanging. But the absence of tissue reaction does not exclude antemortem hanging. Out of the 33 cases of hanging, fracture of hyoid bone were seen in 3 cases and the individuals were aged more than 40 years and a hard ligature was used.[5]

He quoted that if the ligature material is tough and narrow, the mark is expected to be deep and prominent, but if the material is soft and broad, mark is less prominent and less deep. It may be at the level of the thyroid cartilage in about 15% and below the cartilage in about 5% of hangings. In complete hanging, the ligature mark is more prominent as compared to partial hanging. In most hangings, fixed loop is applied when the mark appears in the form of a groove or furrow, being deepest opposite to the knot. Mark is generally yellowish or yellowish brown shortly after death and gets dried and assumes parchment like consistency. Fracture is more frequent in persons over 40 years. Fracture of the superior horn of the thyroid cartilage are approximately equal to fractures of the greater horn of the thyroid bone and related to state of ossification of these structures.[6]

A study of 75 case of violent asphyxial deaths between 1999 and 2002 at the All India Institute of Medical Sciences, New Delhi showed that out of 60cases of hanging 36 were males and 24 were females. Out of the 60cases 26 were in the age group of 21to 30. Rope (plastic & fibre) was used as ligature in 25cases of hanging, dupatta was used in 16cases of hanging, saree in 10 cases, bed sheet in 3 cases, lungie in 2 cases, plastic water pipe in 2 cases, ligature material not known in others. Out of the 60 cases in 58 cases (96.92%) the ligature mark was placed above the thyroid cartilage and 2 cases (3.08%) showed mark at the level of thyroid cartilage. In all the

Create PDF files without this message by purchasing novaPDF printer (http://www.novapdf.com)

60 cases of hanging, the ligature mark was placed obliquely. In all the 60 cases of hanging the ligature mark was not completely encircling the neck circumference. Ligature mark was single in 59 cases of hanging and multiple in only one case. The ligature mark was reddish brown in colour in 25cases of hanging (41.66%), pale in 13 cases (21.66%) and parchmentisation was seen in 22 cases (36.66%). The colour of ligature mark depends largely on the duration of suspension of the body and the nature of the ligature material used.[7]

They quoted in 2002 that the antemortem nature of hanging is ascertained by salivary dribbling from the mouth, Lefacie sympathique, biochemical markers and microscopic study of ligature mark revealing vital reaction. When a tough ligature material like coir or nylon rope is used, produces "rope burn" which also signifies antemortem hanging. They are caused by the friction of rope against skin & such friction generates heat, which produces blisters (second degree burns) by expressing tissue fluid into upper layers of skin, measuring 1-3 mm in diameter as also described by Werner V Spitz. A careful and meticulous examination of neck is necessary in all cases of hanging, or else vital evidence could be lost. However possibility of blisters being produced after death due to putrefaction should be in mind, but analysis of blister contents will unreveal the mystery. Therefore rope burns (blisters) around the ligature mark helps to ascertain antemortem nature of hanging which is one of the periligature injuries and thus of immense value in the course of investigation.[8]

According to him the hanging mark almost never completely encircles the neck unless a slip knot was used, which may cause the noose to tighten and squeeze the skin through the full circumference of the neck. Successful hanging can occur from low

Create PDF files without this message by purchasing novaPDF printer (http://www.novapdf.com)

suspension points. The mark is usually situated higher on the neck than in strangulation, usually being directly under the chin anteriorly, passing around beneath the jaw once and rising up at the sides or back of the neck to usual gap under the knot. In the neck tissues, there may be no findings if a soft ligature has been used. However, the literature suggests that an average figure for the incidence of soft tissue hemorrhages would be about 20 – 30 % of cases and for laryngeal fractures approximately, 30 – 45 % of the cases. Fractures of both hyoid and thyroid may be seen.[9]

He quotes the ligature mark leaves distinct furrow of its own width and pattern on the skin surface. In general, the thinner and tougher the material used, more pronounced is the ligature mark. Similarly, the softer and broader the material, less distinct is the ligature mark. Skin in the region of the ligature mark is dry and hard. Pattern of the ligature used often gets imprinted on the skin as pressure abrasion. Grooving of the ligature mark is due to congestion and associated oedema. These are generally more marked near the upper border of the mark. The ligature groove will be deepest on the opposite side of the knot when the noose is tied with fixed knot. Microscopically, the ligature mark displays the usual characteristics of abrasion showing desquamation and flattening of cells of the epidermis. If death has occurred quickly, vital reaction may be quite difficult to demonstrate. Hyoid bone fracture is seen occasionally in individuals more than 40 years of age and in whom greater cornua have fused with the body.[10]

They undertook a study at Jamnagar in 2002 comprising of 23 cases of hanging deaths. 15 victims were male and 8 were female. The age range was from

Create PDF files without this message by purchasing novaPDF printer (http://www.novapdf.com)

11years to 80 years and the commonest group was between 21-30 years. Most commonly used ligature material was cotton rope followed by saree and nylon rope. Fixed noose was found in 52.2% cases, sliding noose in 39.1% and without noose in 8.7% of cases. 39.2% of the cases were typical hanging and 60.8% were atypical hanging. 60.8% of cases were completely suspended, while 39.2% of the cases were partially suspended. The highest level of ligature was at the back of the neck in most of the cases. In 69.6% cases duration of suspension was less than 6 hours, in 17.4% it was between 6-12 hours and in 8.7% it was more than 12 hours. Duration of suspension was not known in 4.3% of the cases. In 39.1% of cases breadth of ligature mark was less than 1 cm, in 30.4% cases it was 1-2 cm and in 4.3% of cases it was 4-5 cms. In 4 cases(17.4%) injury to the hyoid bone was observed and no other osteo cartilagenous structure was found to be involved. In hanging ligature mark is commonly located in upper part resulting in compression on the hyoid bone to greater extent as compared to rest of osteo cartilagenous structures. The incidence of injury to hyoid bone is increasing with increase in age upto 50 years and with typical and complete type of hanging. The incidence of injury to hyoid bone was higher in cases with highest level of ligature mark at the back of middle of neck. The incidence of fracture of hyoid bone is higher in cases not showing congestion of face. The incidence of fracture increases with increase in duration of suspension and is higher with narrow ligature mark.[11]

They quoted in 2003 that ligature mark is a vital evidence in asphyxial deaths. The course and direction of ligature mark helps in determining the type of asphyxial death as hanging or strangulation. The pattern and direction of the nail marks over the

Create PDF files without this message by purchasing novaPDF printer (http://www.novapdf.com)

neck will help us to interpret the nature of their causation, throttling or suicidal hanging. A victim may often try to extricate or remove the ligature by using his or her hand. During the process of removal of the ligature the nails of the victim produces periligature injuries, which are on examination revealed to be scratch abrasions. In victims of ligature strangulation such scratches may be found near the ligature mark and are usually vertical, but may be irregular or crescentic. The victims of suicidal hanging may attempt to pull away the ligature as a reflex action to preserve life, thus inflicting nail marks on the neck. In attempted resuscitation, nail marks can also be produced by the rescuer while trying to remove the ligature. In case of hanging apart from giving an opinion on the cause of death, the forensic pathologist has to comment on the nature of hanging as antemortem or postmortem.A saliva dribble mark is the classical feature of antemortem hanging, but may not be present in all cases. Rope burns which are produced when tough ligature material like coir or nylon rope is used because of friction between skin and ligature material helps us to ascertain antemortem nature of hanging. It is vital to correlate them with other findings before opining the manner of death.[12]

They did a retrospective study of suicidal hangings on 175 cases in Belgrade in 2003 and the study population was divided in 4 groups according to the position of the ligature knot (24 were anterior, 21 were right, 22 were left, and 108 were posterior hanging). 133 male victims and 42 female victims all aged between 10 and 87 years were studied. The authors analyzed all visible injuries of soft tissues and bones and cartilage of the neck, and in 150 cases (85.7%), they established that there was at least one injury of these structures. The most frequent injury was to sternocleidomastoid

Create PDF files without this message by purchasing novaPDF printer (http://www.novapdf.com)

muscles. Fracture of throat skeleton was detected in 119 cases (68%). A 2-fold fracture of the greater horn of hyoid bone occurred in 7 cases (3 posterior and 3 anterior hangings and 1 right hanging). A single fracture of the left greater horn of the hyoid bone was found in 14 cases, while a fracture of the right greater horn of the hyoid bone occurred in 12 cases. Horn thyroid cartilage fractures accompanied by hyoid bone fractures were identified in 5 cases (1 right hanging and 4 posterior hangings). A possible mechanism of these fractures is assumed to be the pressure that the horns of these structures exert on to the spine because of a greater traction in the posterior hanging type. There was no clear correlation between frequency of neck injuries and the ligature knot location. The hyoid bone fracture could also be caused by other factors like point of the ligature, and width of the ligature. The conclusion could be that the frequency of the left and right horn thyroid cartilage fractures varies in relation to the location of the ligature knot. Fracture of either the left or right superior horn of the thyroid cartilage is the most frequent in the right hanging type.[13]

According to him ligature mark may be single or multiple, formed into a fixed or sliding noose. The knot may be from a simple half hitch to the barrel like "Hangman's Knot". Padding of Ligature suggests sexual misadventure rather than suicide. Longer the noose, the more elongated and well defined is the inverted V shape of the neck often incomplete at the apex as the head tilts away under its own weight. The mark may be transverse and fully encircling if the ligature joins the neck at a right angle as it may do in partial suspension. Internal injury to the neck in suicidal hanging is usually confined to fracture of glosso laryngeal skeleton, the hyoid or commonly one or both superior thyroid cornua.[14]

Create PDF files without this message by purchasing novaPDF printer (http://www.novapdf.com)

A retrospective study of 101 cases of suicidal hanging deaths at Calcutta in 1965 showed complete hanging in 88 cases and partial hanging in 10 cases. Ligature mark was single in all but one case. In that unique case, ligature mark was in two rows. In most of the cases the knot was slipping type. In about 20% of the cases with the ligature material brought with dead body, the knot was fixed. The site of knot was found in the right side of neck in 53 cases, in the left side of neck in 39, in back of neck in 12, and in chin in 4 cases. Sari was used as ligature material in 20 cases, dhoti in 20, ropes in 41, napkin in 12, wrapper in 3, electric wire in 1, lungi in 2, belt in 1, and chadder in 1. In 73 cases, the ligature mark was above thyroid cartilage. In 27 cases, it was over upper part of thyroid cartilage and in 1 case, it was below the thyroid cartilage. No fracture or dislocation of cervical vertebrae was found. Hyoid bone and larynx were found intact in all cases.[15]

They quoted that the deepest impression is opposite the suspension point, marks are generally deeper on the front and sides of the neck, than at the back where the neck structures are firmer and less accommodating a noose. Impression left on the skin is in the region of the knot, the mark follows an upward course to form an inverted V, the apex of the V corresponding with the site of the knot. Mark is generally yellowish or yellow/brown and often dried. Often a thin line of congestion will be seen above or below the groove at some point but usually the deepest. When the suspension point is behind the ligature may encircle the neck almost horizontally, particularly when it is partial suspension. Two thirds of hanging cases studied below the age of 30 years showed fractures of the superior horn of thyroid cartilage are approximately equal to fractures of greater horn of thyroid.In general the frequency

Create PDF files without this message by purchasing novaPDF printer (http://www.novapdf.com)

with which these fractures occur varies considerably in different series. A detailed microscopic examination of the mark may confirm the presence of effusion of red cells, possibly with separation of fibrin and cellular elements, but no evidence of tissue reaction.[16]

A study of 106 cases of asphyxial deaths by hanging in New York city in the year 1967 showed two cases of accidental hanging deaths and 104 cases of suicidal deaths. Commonest ligature material used was rope. Other ligature materials employed were electric cord, bedsheets, neck ties, scarf, dog leash etc. In 98% of the cases, a furrow was present in the region of the neck and in the majority of the cases, the mark was above the level of thyroid cartilage. In more than 80% of the cases it was an interrupted ligature mark , the colour of the ligature mark varied between yellowish brown to dark brown and with the increased duration of suspension and the type of ligature material used their was a hard ,leathery feel of the skin over the ligature mark. No fracture of the thyroid cartilage or hyoid was found.[17]

In the year 1973 they quoted that, in hanging deaths the ligature mark lies above the level of thyroid cartilage in 80% of cases, at the level of thyroid cartilage in 15% of cases and it lies below the thyroid cartilage in 5%. Both hard and soft ligature materials were commonly employed and atypical ligature marks are common. Although uncommon but a few cases of hyoid bone fractures and fractures of thyroid cartilage were noted.[18]

In a study conducted on fracture of hyoid bone in cases of hanging and strangulation deaths in Hyderabad in the year 1978 on 168 cases of hanging and 30 cases of strangulation deaths the results were noted as follows; In cases of hanging,

Create PDF files without this message by purchasing novaPDF printer (http://www.novapdf.com)

the youngest was a male of 15 years and the oldest was a man of 80 years. 35.7% of cases were in the age group of 20-29 years followed by 20.8% in the age range of 40-49 years and 20.3% of cases in the age range of 30-39 years. 8.3% of the cases were in 50-59 years age group and 6.6% in 60-69 years age group. Of the 168 cases of hanging, 148 (88%) victims were male and 20 (11.9%) females. The material used for hanging were hard materials in 134 males & 13 females and soft material in 14 males & 7 females. The position of the ligature mark of hanging in 152 cases (90.5%) was above the thyroid cartilage and in 16 cases (9.5%) it was across the thyroid cartilage and nil below the larynx. Fracture of hyoid bone was present in 10 cases (6%) of hanging. All cases except one were male and used hard material like rope. 8 of them were aged above 40 years. The fracture occurred in right horn in 7 cases, left horn in 2 cases and was bilateral in one case. The displacement of the posterior small fragment was outward in all the cases. The hyoid bone fracture is usually associated with hemorrhages at the site of fracture.[19]

A study of 201 cases of deaths due to hanging in 1984 showed that 95%were suicidal in nature and majority of the persons were over 50years of age with a male predominance. The scene of hanging mostly was home, point of suspension being banisters, door knobs and clothes hooks on doors.150 cases were partial hanging deaths and only 51 cases were complete hanging. In 185 cases atypical ligature marks were seen and hard ligatures were used in 145 cases and soft ligatures in only 56 cases. Slipping knot was commonly employed with posterior knot mark in the majority of the subjects. Postmortem revealed no fractures of laryngeal cartilages congestive changes were prominent at base of tongue with minimal bruising.[20]

Create PDF files without this message by purchasing novaPDF printer (http://www.novapdf.com)

According to him in hanging deaths complete suspension of the body is noted with atypical ligature marks. The suicidee uses any material that is readily available to commit hanging and commonly the ligature mark lies above the level of thyroid cartilage. In partial hangings ligature marks overriding the thyroid cartilage and below the level of thyroid cartilage were noted. Fractures may occur but are by no means invariable; much depends upon the age of the subject. The ligature may be so firm and applied so rapidly that vital reaction is absent; a false impression of a postmortem origin may be gained.[21]

In a study conducted on 160 cases of suicidal hanging deaths of which 134 cases were studied retrospectively and 26 were studied prospectively. Amongst the 26 cases studied prospectively, the ligature material employed was rope in 20 cases, electric cord in 4 cases and cloth belt in the remaining cases. The level of the ligature mark was above the thyroid cartilage in 20 cases and at the level of thyroid cartilage in 3 cases, in the remaining cases it was not recorded. In the majority of the cases, the ligature mark was yellow or brown and parchmentised, in a few cases, it was bluish, in 3 cases, neck markings had reddish or pink colour suggestive of intravital reaction.[22]

110 cases of hanging deaths at Northern Ireland was studied in 1986 of the 110 cases, 105 cases were suicidal and 5 were accidental. It was observed in the majority of cases, the act took place in the house (71.4%). The most common point of suspension was a rafter, joist or beam (43.8%). It was noted that 53.3% victims were touching the ground, and 42.9% victims were fully suspended. Ligature material commonly used was rope in 51.4% of cases, electric flex in 8.5% cases, belts in 7.6% cases, baler twine in 6.6% cases and washing line in 5.7% cases. 69.5% cases had used a slip knot, 8.6%

Create PDF files without this message by purchasing novaPDF printer (http://www.novapdf.com)

had used a fixed knot. In 7 cases ligature mark was below thyroid cartilage. Bruising of the neck muscle was found in 2.9% cases, one of the horns of the hyoid bone was fractured in 26.7% cases, superior horn of thyroid cartilage fractured in 34.3% cases. In 16.2% of cases both hyoid and thyroid cartilage was fractured. 1 case had fracture of cervical 7th vertebrae.[23]

A prospective study of 61 deaths by hanging at USA in1985 was conducted and it was found that the material used for hanging were rope or clothes line in 32 (52.4%) cases, leather belt in 8 (13.1 %) cases, soft belt or neck tie in 7 (11.47%) cases, a length of sheet or other cloth in 6 (9.8%) cases and other ligature material in 8 (13.1 %) cases. The width of the ligature that was recorded ranged from 25.4 mm or less in 46 (75.4%) cases and was greater than 25.4 mm in 7 (11.4%) cases. The site of the ligature knot was at the left side of the neck in 20 instances (32.8%), at the right side and at the back of the neck in 17 cases (27.9%) each, and at the front of the neck in 3 cases (4.9%). The ligature consisted of a single circumferential wrap in 52 (85.2%) cases, 2 wraps in 6 (9.8%) cases and 3 or more wraps in 3 (4.9%) cases. The length of the ligature material from neck to a fixed point of attachment was less than 305 mm in 5 (8.19%) cases and greater than 305 mm in 41 (67.2%) cases. In reference to the position of the body, 20 (39.3%) victims were found completely suspended and 26 (42.6%) victims were found with only their feet touching the surface. In 6 (9.83%) cases bodies were partially supported and in 4 (6.5%) cases the bodies were largely supported below the suspension point. In 5 (8.9%) cases this could not be ascertained. In 45 (73.7%) of the 61 cases the ligature impression was located superior to the thyroid cartilage prominence. Strap muscle hemorrhage was independent of the age of

Create PDF files without this message by purchasing novaPDF printer (http://www.novapdf.com)

the victim was found in 14 cases. Fractures of the hyoid bone or thyroid cartilage were present in three strap muscle hemorrhages cases. 6 of the 14 cases with hyoid fractures and 5 of the 8 cases with thyroid fractures failed to exhibit either soft tissue or strap muscle hemorrhage. Cervical vertebral fractures were absent in all cases. Fracture of the larynx or hyoid bone were present in 16 (26%) cases and was not identified in 45 cases. The hyoid bone was fractured in 14 (22.9%) cases and the thyroid cartilage was fractured in 8 cases. No fractures of the cricoid cartilages were identified.[24]

A study of 61 cases of hanging deaths in Saudi Arabia in 1994 showed 48 cases of complete hanging and 13 cases of partial hanging, all victims of partial suspension used a soft ligature, most victims used running noose and in majority of the cases, there was a single ligature mark and 6 cases showed multiple ligature marks. 26 cases were suspended from the right side of the neck and 29 from the left, 4 were from the back. Asphyxial signs were more prominent in the complete suspension. Complete suspension by hard plastic clothes showed a deep narrow well defined mark above the level of thyroid cartilage, whereas cases of incomplete suspension by softer cotton cloth showed shallow broad ill defined mark, below the level of thyroid cartilage. The ligature mark was yellow to brown in colour in most cases, however soft ligatures produced faint or pale marks with no apparent abrasions. The level of the ligature mark was low in 15 cases, high in 40 cases. The depth was shallow in 15 cases and deep in 40 cases. The width was more than 2 cms in 21 cases and less than 2 cms in 34 cases.[25]

A prospective study of 80 cases of suicidal hanging deaths at Norway in 1996 showed that there were 41 cases (51.2%)of complete suspensions while 39 cases (48.7%) were incomplete. There were 28 cases (35%)of typical and 52 cases (65%) of

Create PDF files without this message by purchasing novaPDF printer (http://www.novapdf.com)

atypical hangings. In 65 cases (82%) soft ligatures were employed and in the remaining hard ligatures were employed. The ligature mark was single in 68cases (85%) and double in 4cases (5%). The ligature mark as placed above the level of thyroid cartilage in 44cases (55%) and in 34 cases (42.5%) it was overriding the thyroid cartilage and in 2cases(2.8%) it was below the thyroid cartilage. The ligature mark was reddish brown in colour in 25 cases (31.25%) and parchmentisation was seen in 58cases(72.5%). 8 cases (10%) showed fracture of greater cornu of the hyoid bone and in 7cases(9%)their was a fracture of the thyroid cartilage. The highest frequency of fractures was found in atypical complete hangings. Radiography has been recommended prior to dissection. The proportion of fractures seemed to increase with age and possibly also with increase in suspension time.[26]

A 15 year retrospective study of 84 cases of suicidal hanging deaths at United Kingdom in 1992 revealed most victims selected rope for the ligature, either man made or natural fibre. Other materials that were used are wire, chain, flex, belts and various soft materials. A single ligature mark above the level of thyroid cartilage was observed in 70cases(83.33%). In all but one case the mark was oblique and interrupted in that one case which was partial hanging it was a transverse mark overriding the thyroid cartilage. The ligature mark was dry and parchmentised in 72cases(84%).In 60cases(71.42%)the knot mark was on the back of neck with slipping noose. Asphyxial signs in the form of petechial haemorrhages was seen in 72cases(84%). They claim that petechial hemorrhages are the result of increased venous pressure and that their presence in partial hanging indicates venous obstruction without arterial obstruction, whereas their absence in complete hanging is due to mere constriction of

Create PDF files without this message by purchasing novaPDF printer (http://www.novapdf.com)

the neck causing carotid obstruction and thus preventing venous congestion.. It was concluded that petechiae / congestion were not associated with ligature type, it was found that fractures were less likely to be found when a soft ligature was employed.[27]

They studied hanging deaths in infants and children in the year 1993 which were all partial hangings. The ligature mark was like a abrasion furrow or an area of pattern lividity, reflecting the imprint of the overlying ligature. Specifically they were seen in all cases in which cloth was caught on the part of a crib or infant caught in a seat belt etc. In the author's experience, the incidence of asphyxial sign like intense petechiae seems to reflect the degree of body suspension. In suicidal hangings, the ligature tightens rapidly and completely around the neck, effectively occluding both the arteries and veins. When the constriction of the neck is incomplete, petechial hemorrhages will be intense.[28]

In a study of 56 cases of hanging deaths in 1987 he noted 50 were males (90%)and 6 were females(10%) . The location of hanging episodes were mainly home in 24 cases, jail in 15cases and they were mainly classified as inside in 51 cases and outside in 5 cases. Ropes and belts accounted for 50% of instruments used as ligature material. Sheets, electric cords, shirts, towels, linens, and other rare instruments were used in remaining cases the most unusual instruments were a clothes hanger (1case) and the traction rope on an orthopedic device used to commit suicide in a hospital (1case). Belts predominated in jail hangings. Hard ligatures were commonly employed with a fixed loop.40 cases showed complete hanging and partial hanging was seen in 16 cases. Ligature mark was above the thyroid cartilage in 50 cases and in six cases it

Create PDF files without this message by purchasing novaPDF printer (http://www.novapdf.com)

was overriding the thyroid cartilage.Parchmentisation of the ligature mark was seen in only 44 cases.No fracture of the thyrolaryngeal cartilage was detected.[29]

In a study of 80 consecutive cases of asphyxiation deaths due to hanging in Denmark in1988 revealed that the police reports, medical histories, photographs were used as modes for collecting information as to scene of occurrence, complete / incomplete hanging and duration of suspension.77cases (96.2%) were suicidal, 3 cases (3.7%) were accidental. 61 cases(76.2%) were atypical and 19(23.7%) were typical. In 30(37.5%) cases the hanging was complete and in 50(62.5%) cases, it was partial hanging. In 60 cases(76%) the ligature mark was above the thyroid cartilage and in 15 cases(19%) it was overriding the thyroid cartilage and in the remaining it was below the level of thyroid cartilage. In 70 cases(90%) soft ligature materials were employed and in 10cases(10%) hard ligatures were used. Parchmentisation of the ligature mark was observed in only 52 cases(65%).In 3cases(3.7%) fracture of hyoid bone was noted.[30]

Four unusual hanging deaths at Australia were studied in 1988. The first victim, who had undergone total laryngectomy for carcinoma larynx, hanged himself in a standing position with a cord ligature. The ligature mark was above the tracheostomy wound in a V shape with intense cyanotic congestion of the face and upper neck.The ligature mark was above the thyroid cartilage with a prominent grooving of the skin with parchmentisation.No internal fractures were detected . The second victim was a known psychotic, who with the help of a rope ligature, hung himself from a tree. The ligature mark was just above the thyroid notch with fresh abrasions of the skin immediately below the ligature consistent with upward slippage of rope during

Create PDF files without this message by purchasing novaPDF printer (http://www.novapdf.com)

suspension.The ligature mark was yellowish brown in colour,with extravasation of blood at the margin of the ligature mark. The third victim had hung herself with a electric cord by partial suspension, with feet touching ground. A circumferential parchment like brown coloured ligature was located round the neck above the thyroid notch and rose to a V at the angle of mandible on the right side with no internal injuries in neck.[31]

In a study of 127 cases of hanging deaths at New Delhi in1998 showed that ligature mark was single in 124 cases and was multiple in 3 cases. The knot was single in 126 cases and multiple in 1 case. Its position was high in 124 cases and middle in 3 cases. The direction was oblique in all the 127 cases. In 126 cases, the ligature mark was incomplete. In 121 cases, the ligature mark was pale and parchmentised, soft and red in 5 cases and ecchymosed in 1 case. Slipping of ligature mark was seen in 24cases. Slipping noose was applied in 98cases. Asphyxial signs in the form of cyanosis, petechial haemorrhages seen in 120cases. Fracture of hyoid bone was seen in 12cases.[32]

They studied 61 cases of hanging deaths in1998, which comprised 43% of all violent asphyxial deaths in Imphal. Ligature mark was oblique in all the 61cases(100%). Ligature turn was single in 96.7% and was double in 3.3% of the cases. In 50 cases (81.96%) the mark was above the level of thyroid cartilage and in 11cases(18.5%) it was overriding the thyroid cartilage. Prominent ligature mark was observed in 47 cases (77.33%). The colour of the ligature mark was reddish in36% of the cases, followed by brown colour in 31.2%. The colour was pale in 19.7%of the cases. Ligature mark showed parchmentization in 13% of cases. Tissues underneath

Create PDF files without this message by purchasing novaPDF printer (http://www.novapdf.com)

the ligature marks were pale in 47.5%, glistening white in 18%, contused in 27.9%. There was extravasation of blood in 6.6%. None of the hanging cases had a fractured thyroid cartilage. The hyoid bone was fractured in 4.9% of the cases.[33]

In the year 1996 they evaluated a total of 109 cases of suicidal or accidental hanging deaths in Germany and the number of hyoid bone or thyroid cartilage fractures or both was investigated in relation to the highest point of the ligature mark and to the age of the deceased. They have divided the hanging victims into 8 groups, depending upon the topographical location of the highest point of the ligature mark. They are Middle of chin, Right anterior, Right ear, Right posterior, Middle of occiput, Left posterior, Left ear and Left anterior. 50% of the cases (four of eight) with a location of the highest point of the ligature mark in front of the ears showed positive results, whereas 68% (69 of 101) of the individuals with a highest point at or behind the ears gave positive findings. Even though a higher incidence of positive results and in particular of multiple fractures could be established in cases with a highest point of the ligature mark at or behind the ears, no clear correlation between frequency and number of throat-skeleton fractures was detectable in our series.[34]

A study of 50 cases of deaths due to hanging in Orissa in 1998 revealed that, 28 were males and 22 were females. Typical and complete hanging was seen in 14cases,atypical and incomplete hanging as seen in 36cases. Rope was used in 26 cases, linen in 16 cases, electric wire in 8 cases as the ligature materials. 38 victims showed intense asphyxial signs with 13 cases showing fracture of the hyoid bone or thyroid cartilage. It seems that typical hanging is especially linked to the fractures and the congestion of the face corresponds to incomplete hanging. Localization of the

Create PDF files without this message by purchasing novaPDF printer (http://www.novapdf.com)

postmortem staining depends on the length of time body is suspended. The study concluded that the frequency of fracture increases with the increase of suspension time.[35]

In the year 1998 they studied 12 cases of paediatric hanging deaths and concluded that asphyxial signs were more prominent in incomplete hanging. 6 cases of complete hanging showed hard ligatures around the neck with deep grooving on the front and sides of neck. Complete suspension leading to rapid death in the children is responsible for the lack of petechial haemorrhages that was seen in the autopsies. In none of the cases fracture of the hyoid bone or thyroid was detected. They concluded that this contrasts with the findings in adult hangings, where the reported incidence of such fractures is as high as 67%.[36]

A retrospective study analyzing 307 accidental and suicidal hangings for the presence or absence of neck organ fractures in U.S.A. in 1999 revealed 275 were males and 42 were females. Sixteen of the ligatures were 0.93cm in width or less. The remainder were wider i.e., 3 cm in belt, wide rope etc. In several of the cases, the ligature consisted of a strip of cloth or piece of clothing. The width of this type of ligature is difficult to define because of its tendency to compress in some regions of the neck while remaining wide in others. The width of the ligature with fractures present was commonly very narrow(<_0.93cm) Therefore, it appears that ligature width also is not of predictive value in whether or not hanging will result in a neck organ fracture. Another variable considered was whether or not the decedent was fully or partially suspended. In this review, full suspension does not appear to be important in producing fractures. This is highlighted by the finding that at least 25 of the 29 cases in which

Create PDF files without this message by purchasing novaPDF printer (http://www.novapdf.com)

neck organ fractures were identified were definitely not or most likely not fully suspended at any point in time. It was concluded that the ligature type does not seem to be of predictive value in causing fractures.[37]

They studied 40 cases of suicidal hanging deaths in the year 2000 and concluded that higher rates of fracture was present with complete suspension. Hard ligature materials were commonly employed by the deceased and atypical ligature marks were observed in 30 cases (90%) .The maximum width produced by the ligature material was 4cms.35 cases(95%)showed ligature mark above the level of thyroid cartilage and 4cases(4%)showed ligature mark overriding the thyroid cartilage and in only one case the mark was below the level of thyroid cartilage. Hyoid bone fracture was noted in 4 cases (4%) and all the 4cases showed complete suspension with hard ligatures.[38]

According to him ligature mark is usually above hyoid bone, oblique and passing backwards and upwards symmetrically on either side to the point of suspension. Mark is not seen at the point of knot or where there is intervening hair or clothing. At times there may be more than one ligature mark when the material has been wound around the neck more than once. In such cases, the skin between the ligature marks will appear bruised due to pinching.[39]

They studied 146 cases of hanging deaths in 2001, out of which 36 cases were partial hanging. Rope was the ligature material in 62%, dhothi in 16%, and other soft material 23% of cases. 39% of the cases showed less than 2.2cms width of the ligature mark and 61% showed more than 2.5 cms. 65% cases showed single ligature mark, 35% double ligature. 77% of cases showed ligature mark above the level of

Create PDF files without this message by purchasing novaPDF printer (http://www.novapdf.com)

thyroid and 23% showed mark overriding the thyroid. Fracture of hyoid bone was detected in 14 percent of cases. 15 percent of cases showed fracture of thyroid cartilage and 16% of cases showed interstitial hemorrhages on the thyroid gland. Fractures were more common in complete hanging than in partial hanging.[40]

In a study conducted at Bangalore in 2001 comprising 246 cases of suicidal hanging deaths. 138(56.08%) victims were male and 108(43.9%) were female. The age range comprised from 14 to 68 years. Majority (86.1%) of the victims were aged below 40 years and only 13.8% of the victims were aged above 40 years. Most hanging deaths occurred indoors (99.5%). Soft materials were used in 63.4% and hard materials were used in 32.9%. 213 cases (86.58%) were complete hanging and 33 cases (13.41%) were partial hanging. 26.42% of the cases were typical hanging and 68.6% were atypical hanging deaths. The position of the knot was occipital in 26.4%, right occipital in 15.4%, left occipital in 17.1%, near the chin in 2.8%, right ear in 16.3%, left ear in 17.1% and not known in 4.9% of cases. Deaths were noticed by the relatives within 8 hours of suspension in 64.22% of the cases and within 8-16 hours in 28.86% of cases. Ligature mark was present in 98.78% of the cases. Ligature mark was present above the level of thyroid cartilage in 75.72% of cases, on the thyroid cartilage in 18.93% and below thyroid cartilage in 5.34% of cases. Skin underneath ligature was hard and parchmentised in all cases, except decomposed cases. The size of the ligature mark varied from 14-42 cms in length and 1cm to 6 cms in breadth. The soft tissue under the ligature mark was pale and glistening in all cases, except in decomposed cases. There was neither extravasation of blood nor muscle

Create PDF files without this message by purchasing novaPDF printer (http://www.novapdf.com)

tears/ruptures/intimal tear of carotid vessels. Hyoid bone and thyroid cartilage were intact/not fractured in all cases.[41]

In a study of 120 cases of hanging deaths at Bangalore in 2005, 28 cases were partial hanging and 92 cases were complete hanging. Ligature material used was soft in 101 cases, where as hard ligature material was used in 19 cases. Slipping type of noose was used in 105 cases and fixed noose was used in 15 cases. Height of suspension was more than 5 feet in 17 cases and it was less than or equal to 5 feet in 103 cases. The ligature mark was single in 117 cases and double in 3 cases. The mark was situated above the level of thyroid cartilage in 95 cases, overriding thyroid cartilage in 20 cases and below thyroid cartilage in 5 cases. The width of the ligature mark was about 1.5 cms or less in 32 cases, 2-2.5 cms in 61 cases, and above 3 cms in 27 cases. The highest point of ligature mark on the neck was on the right occipital region in 34 cases, left occipital region in 32 cases, occipital region in 31 cases, right or left ear in 20 cases and right front of neck in 3 cases. The fracture of the hyoid bone was found to be less common than thyroid cartilage fracture. Left greater horn fracture of hyoid bone was more common in hanging. No clear association between the side of fracture and the site of knot is found in hanging. Compared with single ligature mark, double ligature mark on the neck was found with higher frequency of fractures. No fractures of hyoid bone were present, when the ligature mark was below the level of thyroid cartilage and also when the highest level of ligature mark of hanging was in front of ears. The fracture of hyoid bone was found to be not influenced by the completeness of suspension, typical or atypical ligature mark when the knot was behind ears, width of the mark and whether the level of the mark was above or overriding the thyroid

Create PDF files without this message by purchasing novaPDF printer (http://www.novapdf.com)

cartilage. The hyoid bone fracture is very unlikely in a hanging victim from a height of 5 feet or less, using a soft ligature material. When the ligature mark is below the level of thyroid cartilage, fractures of hyoid bone are very unlikely. When the highest level of ligature mark of hanging is in front of ears, the hyoid bone will be reasonably intact.[42]

Create PDF files without this message by purchasing novaPDF printer (http://www.novapdf.com)

MATERIALS AND METHODS

The present study "Study of ligature mark in cases of Hanging" has been carried out in the Department of Forensic Medicine, M.S.Ramaiah Medical College and Hospital, Bangalore during the period of 2004 to 2005. Of all the cases brought to the department for medicolegal autopsy, cases in which death had resulted from hanging were identified. A sum total of 80 cases were selected for this prospective study. Permission of the ethical committee on the use of human material for research purpose was obtained.

Detailed information regarding the deceased and the circumstances of death was collected from the police and relatives. In some of the instances, this information was supplemented by either, visit to scene of occurrence or from the photographs of scene of occurrence.

SAMPLE SIZE DETERMINATION

Sample size is estimated based on the assumption that this method can approximately detect ligature marks in 90% of the cases. The sample size is estimated based on 5% significance level and 8% error.

p = 90%, q = 10% and E = 7.2 for 8% error.

$$\text{The sample size, } n = \frac{Z\alpha^2 \times pq}{E^2} = \frac{4 \times 90 \times 10}{(7.2)^2}$$

n = 73. Hence the number of cases to be studied: 80.

Create PDF files without this message by purchasing novaPDF printer (http://www.novapdf.com)

INCLUSION CRITERIA

All the cases brought with a history of hanging.

EXCLUSION CRITERIA

Decomposed bodies where the ligature mark is masked.

The hanging victims were classified on various characteristics as follows:

A. Type of suspension: 1.Complete.

2.Partial.

B. Type of ligature mark produced: 1.Typical.

2.Atypical.

C. Duration of suspension:

1. Duration of suspension less than 1 hour.
2. Duration of suspension between 1hour to 5hours.
3. Duration of suspension beyond 5 hours.

The duration of suspension was calculated by the history (time duration when the victim was last seen alive) and the autopsy findings.

Observations made during the autopsy included external examination and internal examination of the deceased. The ligature material was studied, whenever the ligature material was in situ study of the noose as slipping or fixed, number of turns and site of the knot in relation to neck was noted.

The ligature materials were classified into two groups: Hard ligature materials and soft ligature materials. Ropes, metallic chains, etc were considered as hard. While saree, dupatta, lungi and towel etc were considered to be soft ligature materials.

Create PDF files without this message by purchasing novaPDF printer (http://www.novapdf.com)

External examination of the neck was conducted to study the ligature mark/s and other periligature injuries. Number of ligature mark/s, topographical location of the highest level of ligature mark, width of the mark, orientation of the mark, level of ligature mark in relation to the thyroid cartilage and other features were noted. Skin over the ligature mark was sent to department of Pathology at M.S.Ramaiah Medical College and Hospital for histopathological examination to note the nature of ligature mark as antemortem or postmortem.

Classification of ligature marks based on the topographical location of the highest level of the ligature mark is as below:

Level I =right front of neck.

I,II =below right ear.

II = right back of neck.

II,III =center of Back (occipital, typical ligature mark)

III = left back of neck.

III,IV = below left ear.

IV =left front of neck.

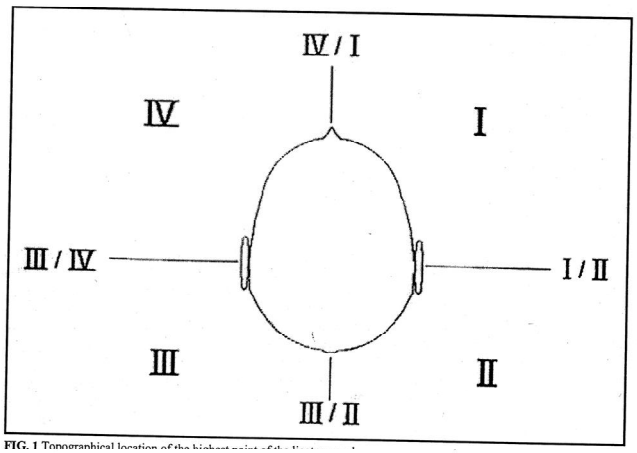

FIG. 1 Topographical location of the highest point of the ligature mark

Create PDF files without this message by purchasing novaPDF printer (http://www.novapdf.com)

RESULTS AND DISCUSSION

Age and Sex distribution in the study population.

TABLE 1 : Age

Sl. No	Age (years)	No. of cases	%
1	10-19	20	25
2	20-29	30	38
3	30-39	18	23
4	40-49	7	9
5	50-59	3	4
6	> 60	2	1
	Total	80	100

TABLE 2 : Sex

Sl. No	Sex	No. of cases	%
1	Male	47	59
2	Female	33	41
	Total	80	100

It is observed from the above table that maximum no of hangings in the study population are seen in the age group 20-29 years (38%) followed by 10-19 years (25%) and 30-39 years (23%). In the sex distribution pattern males accounted for 47 cases (59%) as compared to 33 cases (41%) in females.

The influencing factors for the above distribution being unemployment, love disappointment, marital disharmony, financial problems, dowry harassment etc.

Similar findings were observed in the studies conducted by B.K.Sen Gupta[15], Gary. P. Paparo and Siegel.H,[22] Andrew Davison and Marshall T.K.[23],Ryk James and Paul Sillocks[27] ,A. Momonchand, Th.Meera Devi and L.Fimate[33] G.A. Sunil Kumar Sharma,O.P.Murthy,T.D.Dogra.[7]

It is in contrast to the findings observed by James L. Luke,[17] David A.L.L Bowen.[20] For these studies were done in developed countries, where in there is ample employment opportunities, westernized culture and good governmental support programmes.

Create PDF files without this message by purchasing novaPDF printer (http://www.novapdf.com)

Fig 1 : Age Distribution in the study population

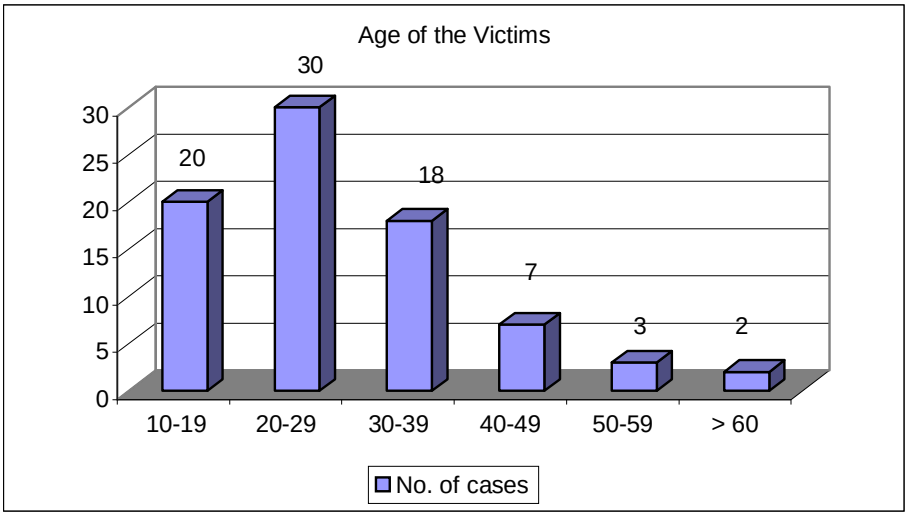

Fig 2 : Sex Distribution in the study population

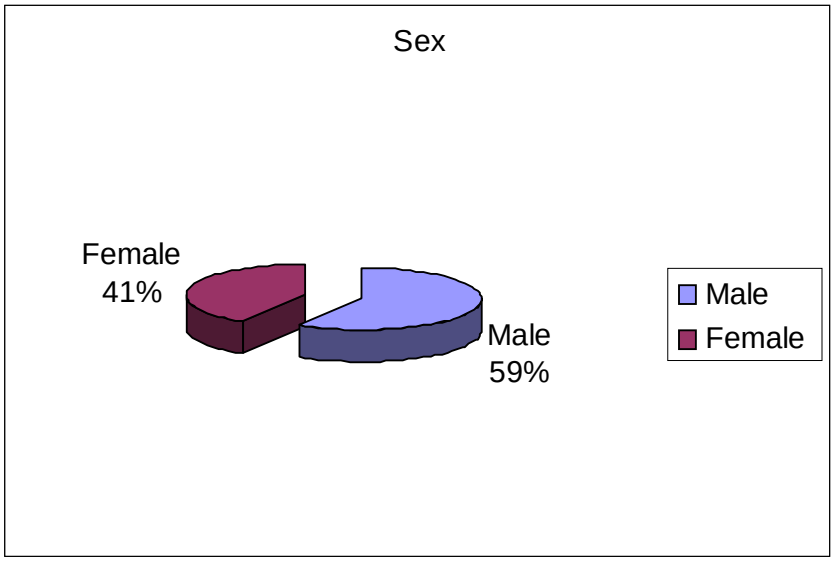

Create PDF files without this message by purchasing novaPDF printer (http://www.novapdf.com)

Distribution in the study population according to the type of hanging (suspension and ligature mark)

TABLE 3 : Degree of Suspension

Sl. No	Degree of Suspension	No. of cases	%
1	Partial	17	21
2	Complete	63	79
	Total	80	100

TABLE 4 : Ligature Mark

Sl. No	Ligature mark	No. of cases	%
1	Typical	11	14
2	Atypical	69	86
	Total	80	100

In the present study it is observed that complete suspension were noted in 63 cases (79%) as compared to 17 cases (21%) of partial suspension.

Atypical ligature mark were noticed in 69 cases (86%) as compared to typical ligature mark in 11 cases (14%)

The above observations were similar to the findings observed by Jorn Simonson,[30] Elfawal M.A, O.A. Awad,[25] Feigin Gerald,[37] Andrew Davison and Marshall T.K.[23]

The influencing factors being the majority of the study population were adult individuals who had committed suicides and hence more number of complete hanging. The position of the knot or any intervening object like clothings, bony projections (angle of the jaw), long plaits in Indian women and also the beard accounted for the majority of the mark being atypical.

It is in contrast to the findings observed by Gary P. Paparo,[22] I. Morild,[26] Jonathan P. Wyatt,Wyatt P.W.,Squires T.J.,Busuttil A [36].BalabantarayJ.K.[35] The reasons being that their study population was restricted to victims of lower age group, who had been either victims of accidental hanging or homicidial hanging.

Create PDF files without this message by purchasing novaPDF printer (http://www.novapdf.com)

Fig 3 : Distribution in the study population according to the type of hanging

Suspension

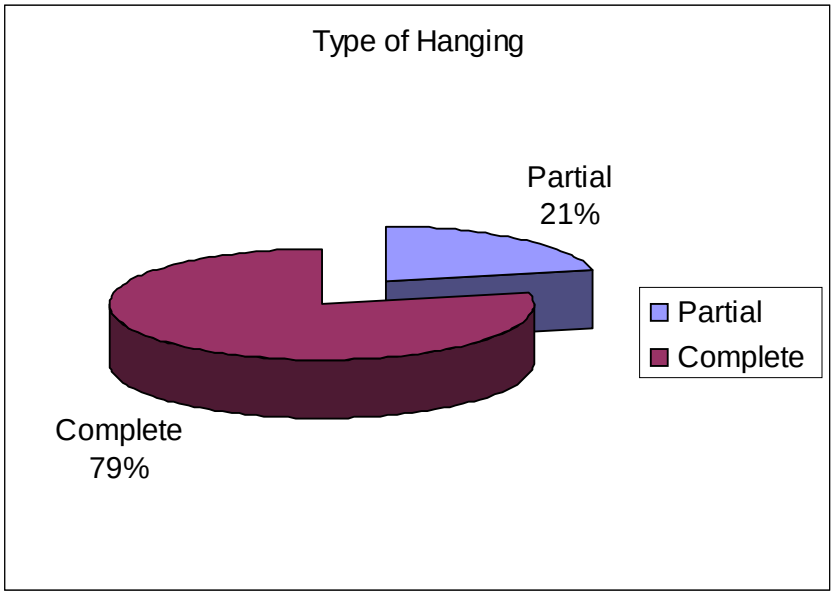

Fig 4 : Distribution in the study population according to the type of hanging

Ligature mark

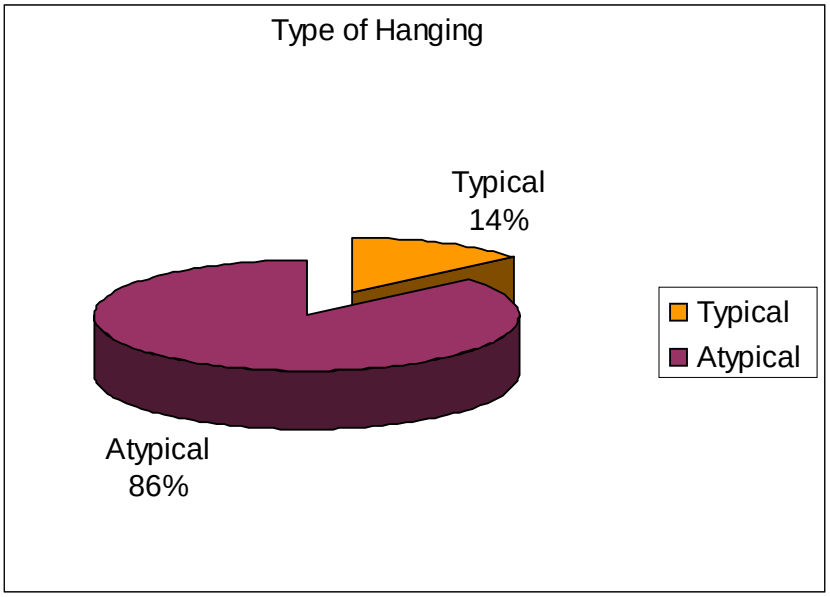

Create PDF files without this message by purchasing novaPDF printer (http://www.novapdf.com)

Distribution among the study population with respect to multiplicity of Ligature mark

TABLE 5 : Number of Ligature marks

Sl. No	Number of Ligature marks	Number of victims	%
1	One	76	95
2	Two	2	3
3	Three or more	1	1
4	Nil	1	1
	Total	80	100

In the present study it is observed that single ligature mark is seen in 77 cases (97%) as compared to double ligature mark in 2 cases (2%) and more than two ligature marks in 1 case (1%).

Similar findings were observed in the studies conducted by A.Momonchand, Th.Meera Devi,L.Fimate[33] ,Sunil Kumar Sharma, O.P.Murthy, T.D.Dogra[7] .M.P. Sarangi.[32] .The reason for single ligature mark being the choice of ligature material in the majority of cases, which were strong, long and broad in nature, so as to fulfill the need. The reason for double ligature mark being the usage of rope with double noose one passing over the chin and the other one passing over the middle of the neck with a left posterior fixed knot in one case and in the other one due to slipping of the ligature and multiple ligature mark observed due to multiple rounds of the material passed round the neck. The reason for absent / faint ligature mark being a soft material that was used (Saree) and the duration of suspension was very less (30 Minutes).

Create PDF files without this message by purchasing novaPDF printer (http://www.novapdf.com)

Fig 5 : Distribution in the study population with respect to multiplicity of ligature mark.

Number of Ligature marks

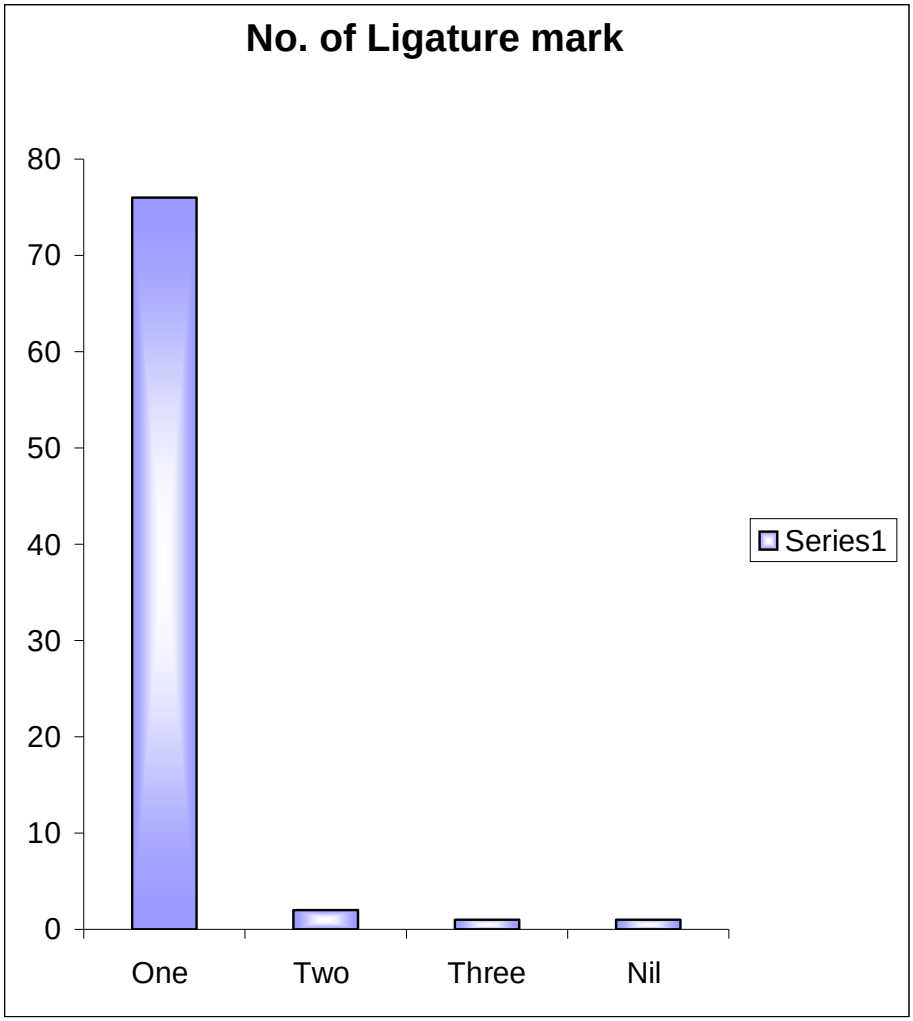

Create PDF files without this message by purchasing novaPDF printer (http://www.novapdf.com)

Distribution among the study population according to the level of ligature mark

TABLE 6 : Level of ligature Mark

Sl. No	Level of ligature mark	No. of victims	%
1	Above the thyroid Cartilage	63	79
2	Overriding the thyroid cartilage	13	16
3	Below the thyroid Cartilage	4	5
	Total	80	100

In the present study it is observed that in 63 cases (79%) the level of the ligature mark was above the thyroid cartilage, below the level of thyroid cartilage in 4 cases (5%) and over riding the thyroid cartilage in 13 cases (16%).

Similar findings were observed in the study conducted by M.P. Sarangi,[32] G.A. Sunil Kumar Sharma, O.P.Murthy,T.D.Dogra[7],Elfawal M.A and O.A. Awad,[25] James L Luke,[17] Betz .P. and Eisenmenger .W.[34],Gary .P. Paparo and Siegel.H..[22]

The reasons for the majority of the mark level being above the thyroid cartilage can be attributed to the complete suspension of the body with posterior knot positioning which causes the material to slide upwards and the factor for the mark to be below the thyroid cartilage is either due to partial suspension or due to a prominent thyroid cartilage.

Create PDF files without this message by purchasing novaPDF printer (http://www.novapdf.com)

Fig 6 : Distribution in the study population according to the level of ligature mark

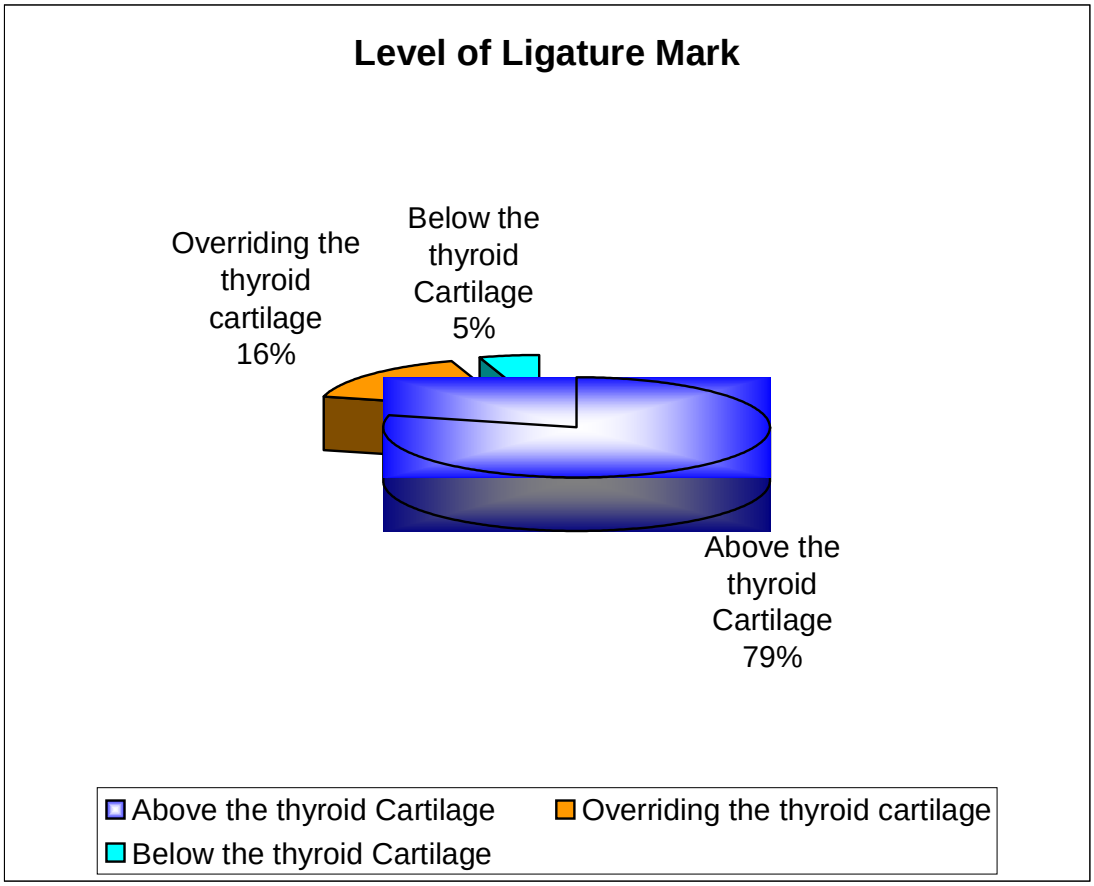

Create PDF files without this message by purchasing novaPDF printer (http://www.novapdf.com)

Distribution in the study population according to the breadth of the ligature mark

TABLE 7 : Breadth of the Ligature Mark

Sl. No	Breadth of ligature mark	Number of victims	%
1	<1 cms	4	5
2	1-2 cms	50	62
3	2-3 cms	23	29
4	> 3 cms	3	4
	Total	80	100

It is observed in the present study population that in 50 cases (63%) the breadth of the mark was 1 to 2 cms, 2 to 3 cms in 23 cases (30%), more than 3 cms in 3 cases (3%) .

Similar results were observed in the studies conducted by GA sunil Kumar Sharma, O.P.Murthy and T.D.Dogra[7],Ryk James and Paul Sillocks,[27] M.P. Sarangi,[32] Elfawal M.A.and O.A. Awad,[25] as the breadth depends solely on the width of the ligature material used and so also the multiplicity of the ligature material.

Create PDF files without this message by purchasing novaPDF printer (http://www.novapdf.com)

Fig 7 : Distribution in the study population according to the breadth of ligature mark

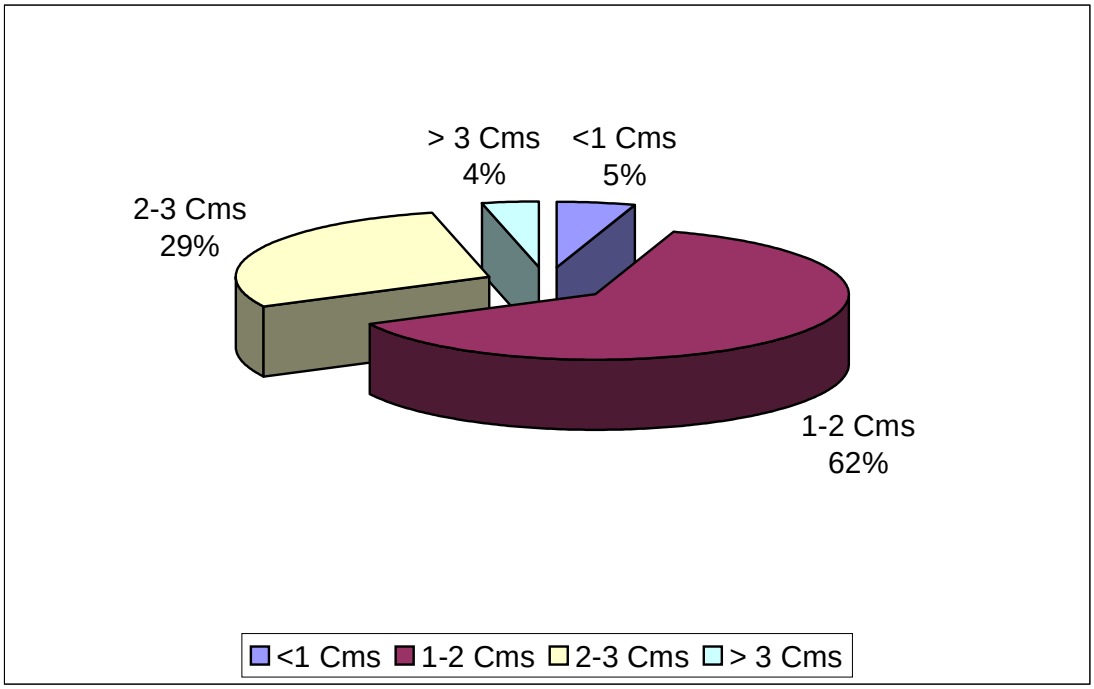

Create PDF files without this message by purchasing novaPDF printer (http://www.novapdf.com)

Distribution in the study population with respect to character of the ligature mark

TABLE 8 : Characteristics of ligature mark

Sl. No	Character of the ligature mark	Number of victims	%
1	Continuous	3	4
2	Interrupted	77	96
3	Faint	17	21
4	Prominent	63	79

In the present study it is noted that 77 cases (95%) had a interrupted ligature mark as compared to the continuous type in 3 cases (3%). The mark is prominent in 63 cases (79%) and faint in 17 cases (21%).

The present study tallys with the findings observed in the studies conducted by M.P. Sarangi[32] . G.A. Sunil Kumar Sharma, O.P.Murthy and T.D.Dogra[7],C.B. Jani and B.D. Gupta,[11] Nikolic Slobadan,Micic Jelena,Atanasijevic Tatjana,Djokic Vesna and Djonic Danijela[13] .The reason for the majority being an interrupted ligature mark is complete suspension, of suicidal in manner and prominent mark is due to the type of the material being strong and also increased period of suspension.

Create PDF files without this message by purchasing novaPDF printer (http://www.novapdf.com)

Fig 8 & 9 : Distribution in the study population with respect to character of the ligature mark

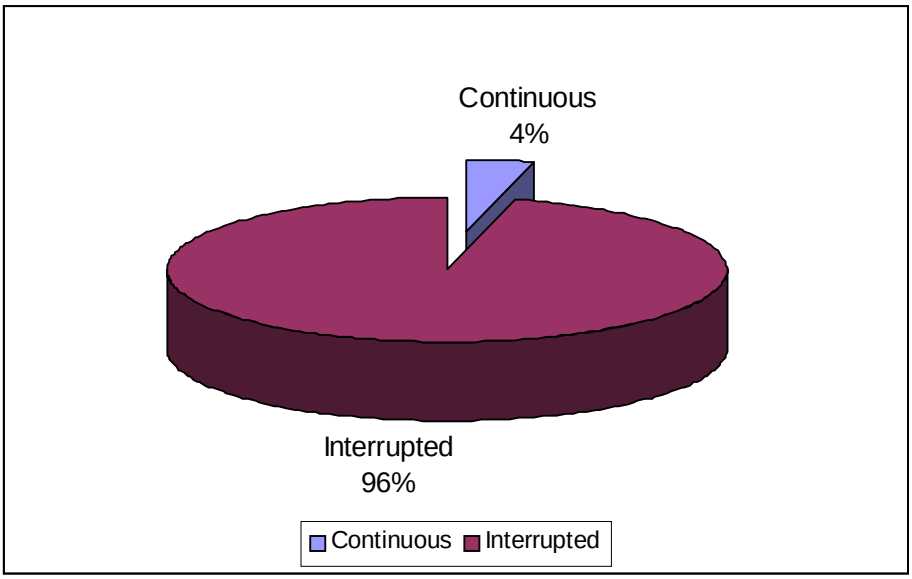

Create PDF files without this message by purchasing novaPDF printer (http://www.novapdf.com)

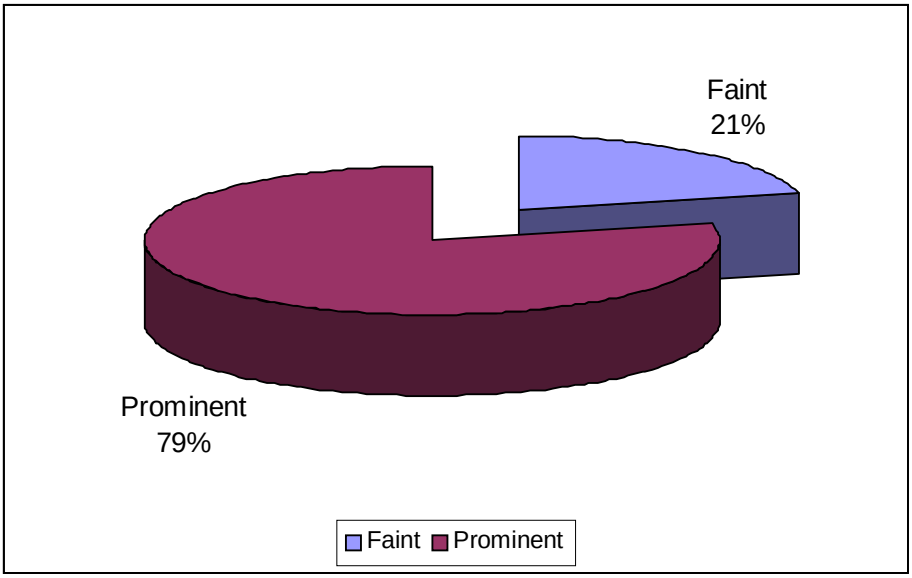

Distribution among the study population according to the periligature injuries.

TABLE 9 : Periligature Injuries.

Sl. No	Periligature Injuries.	Number of victims	%
	Rope burns as: Periligature injuries		
1	Present	10	10
2	Absent	70	90
	Total	80	100
	Other Periligature injuries		
3	Present	11	14
4	Absent	69	86
	Total	80	100

In the present study 69 cases (86%) did not show any changes around the ligature marks, but in 11 cases (14%) periligature injuries in the form of abrasions, ecchymoses and rope burns (10% of cases) were seen.

Create PDF files without this message by purchasing novaPDF printer (http://www.novapdf.com)

The rope burns are due to the heat generated by the friction of the ligature material against the skin due to slippage of the material producing blisters. The above features were observed in the studies conducted by Pradeep Kumar .G.,Manoj Kumar Mohanty,Shanavaz Baipady.[8]

The factors for the production of other periligature injuries being the nail scratch marks inflicted by the struggling victim to free himself, fibres projecting from the material and knot mark bruising.

Fig 10 & 11 : Distribution in the study population according to the periligature injuries.

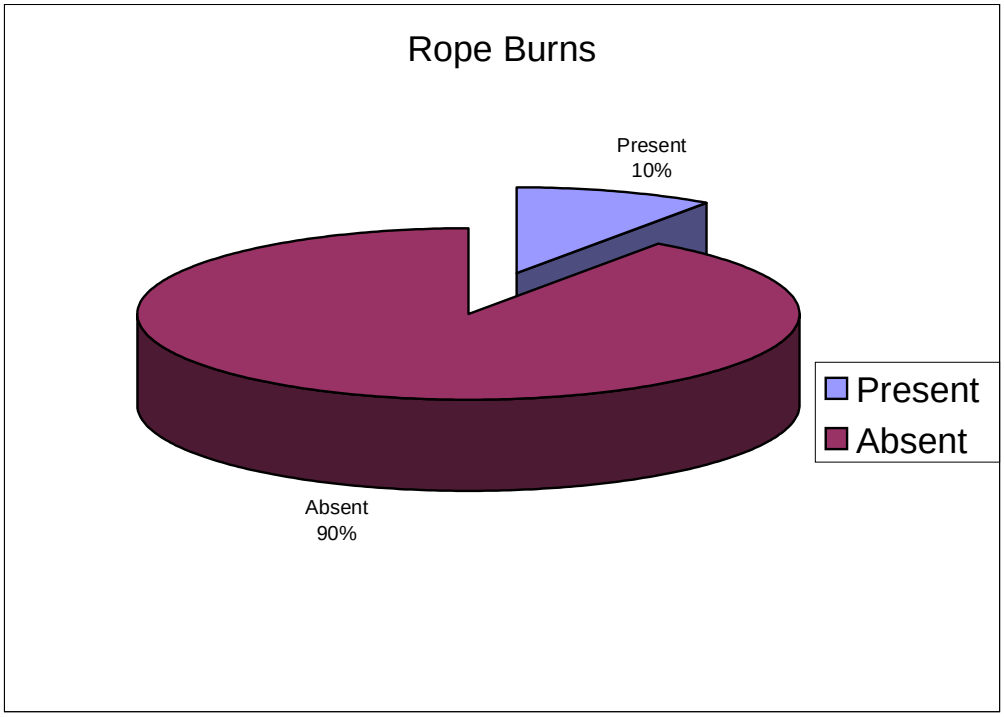

Create PDF files without this message by purchasing novaPDF printer (http://www.novapdf.com)

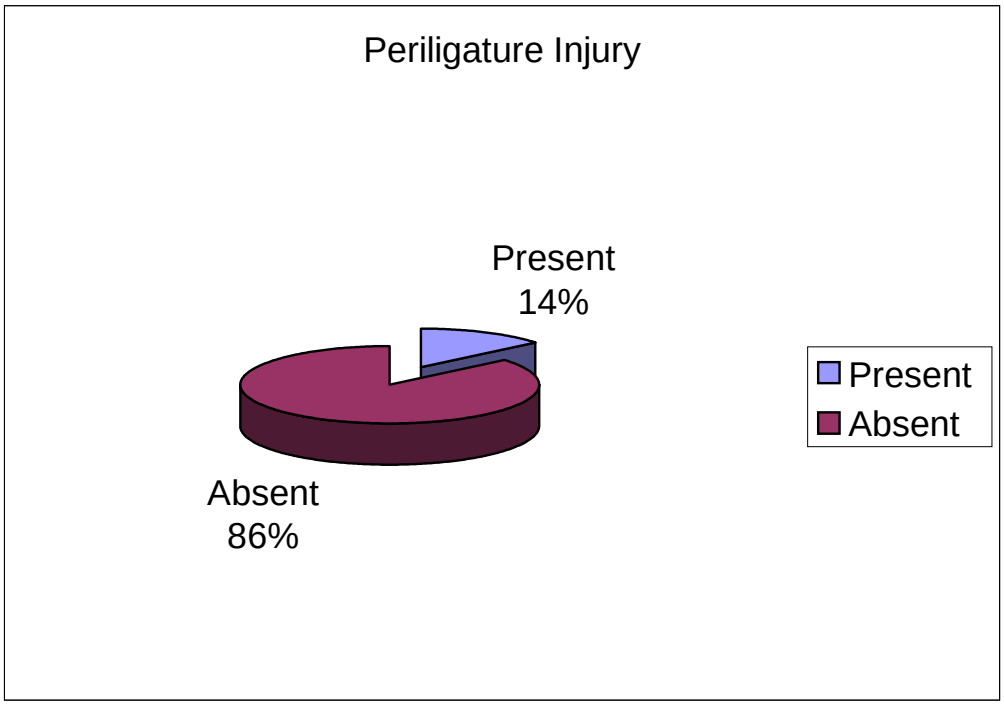

Distribution in the study population with respect to the texture and parchmentisation of the ligature mark

TABLE 10 : Texture of the ligature mark and Parchmentisation of the ligature mark

Sl. No	Texture of the ligature mark	Number of victims	%
1	Rough	61	76
2	Smooth	19	24
	Total	80	100
	Parchmentisation of the ligature mark		
3	Present	62	77
4	Absent	18	23
	Total	80	100

Create PDF files without this message by purchasing novaPDF printer (http://www.novapdf.com)

In the present study it is observed that in 61 cases (76%) the ligature mark was rough, and smooth in 19 cases (24%). Parchmentisation was seen in 62 cases (77%), and absent in 18 cases (23%) Similar results were seen in the studies done by M.P. Sarangi,[32] B.K Sen Gupta,[15] Gary. P. Paparo and Siegel .H.,[22] James L Luke, Reay D.T.,Eisele J.W. and Bonnell H.J.,[24] Andrew Davison and Marshall T.K.[23]

Reasons for the above observations being the form of ligature material and the duration of suspension leading to the parchmentisation in the majority of cases.

Fig 12 & 13 : Distribution in the study population with respect to the texture and parchmentisation of the ligature mark

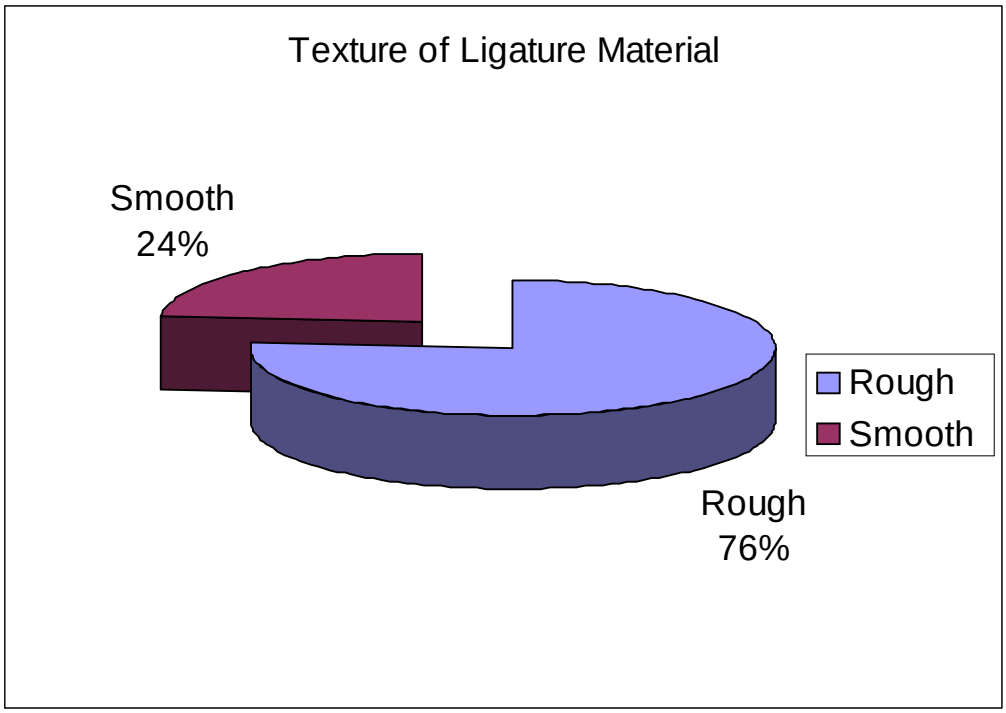

Create PDF files without this message by purchasing novaPDF printer (http://www.novapdf.com)

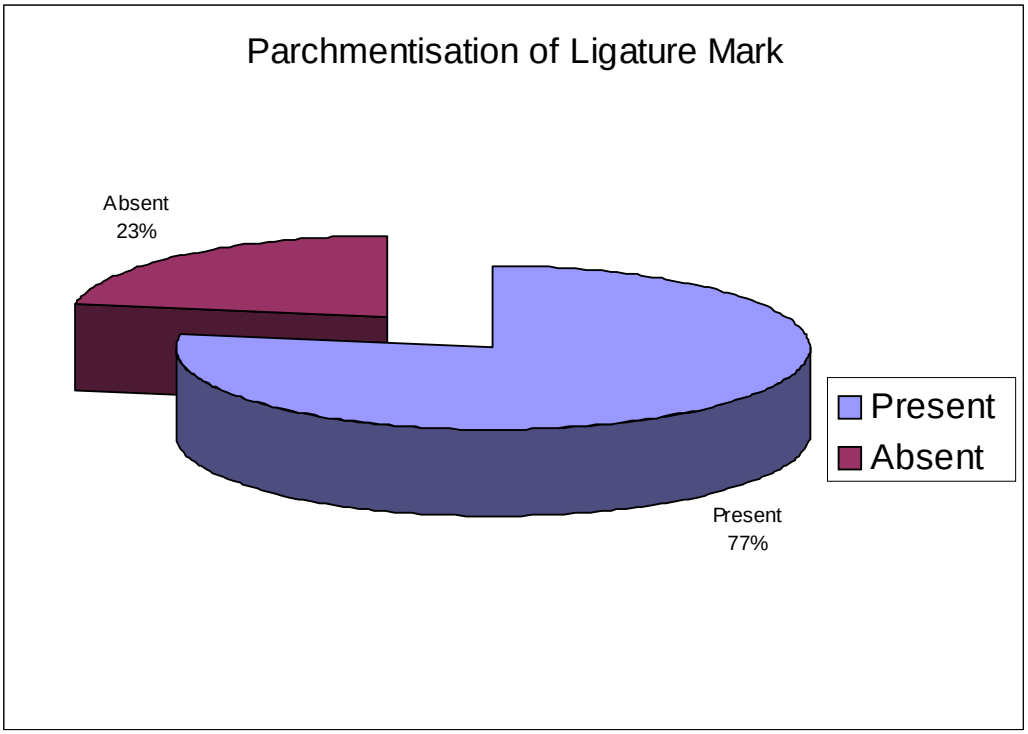

Distribution in the study population according to the colour of ligature mark

TABLE 11 : Colour of Ligature Mark

Sl. No	Colour of ligature mark	No. of victims	%
1	Pale	14	18
2	Red	19	24
3	Yellowish Brown	21	26
4	Dark Brown	26	32
	Total	80	100

Duration of suspension and the ligature materials used with relation to the colour of the ligature mark.

No. of victims	< 1 hr Pale to red	1- 5hr Yellowish brown to dark brown	> 5 hr Dark brown

Create PDF files without this message by purchasing novaPDF printer (http://www.novapdf.com)

	Soft	Hard	Soft	Hard	Soft	Hard
14	10	4	-	-	-	-
19	9	10	-	-	-	-
21	-	-	15	6	-	-
26	-	-	-	-	10	16

In the present study in 26 cases (32%) the mark was dark brown, in 21 cases (26%) Yellowish brown, in 19 cases (24%) red, and mark was pale in 14 cases (18%). Similar findings were observed in the studies conducted by Andrew Davison and Marshall T.K.[23],G.A. Sunil Kumar Sharma, O.P.Murthy and T.D.Dogra[7],A. Momonchand, Th.Meera Devi and L.Fimate[33],M.A. Elfawal and O.A. Awad.[25]

The reason being the colour of the ligature mark depends on the duration of suspension and the complexion of the person.

Fig14 : Distribution in the study population according to the colour of the ligature mark

Create PDF files without this message by purchasing novaPDF printer (http://www.novapdf.com)

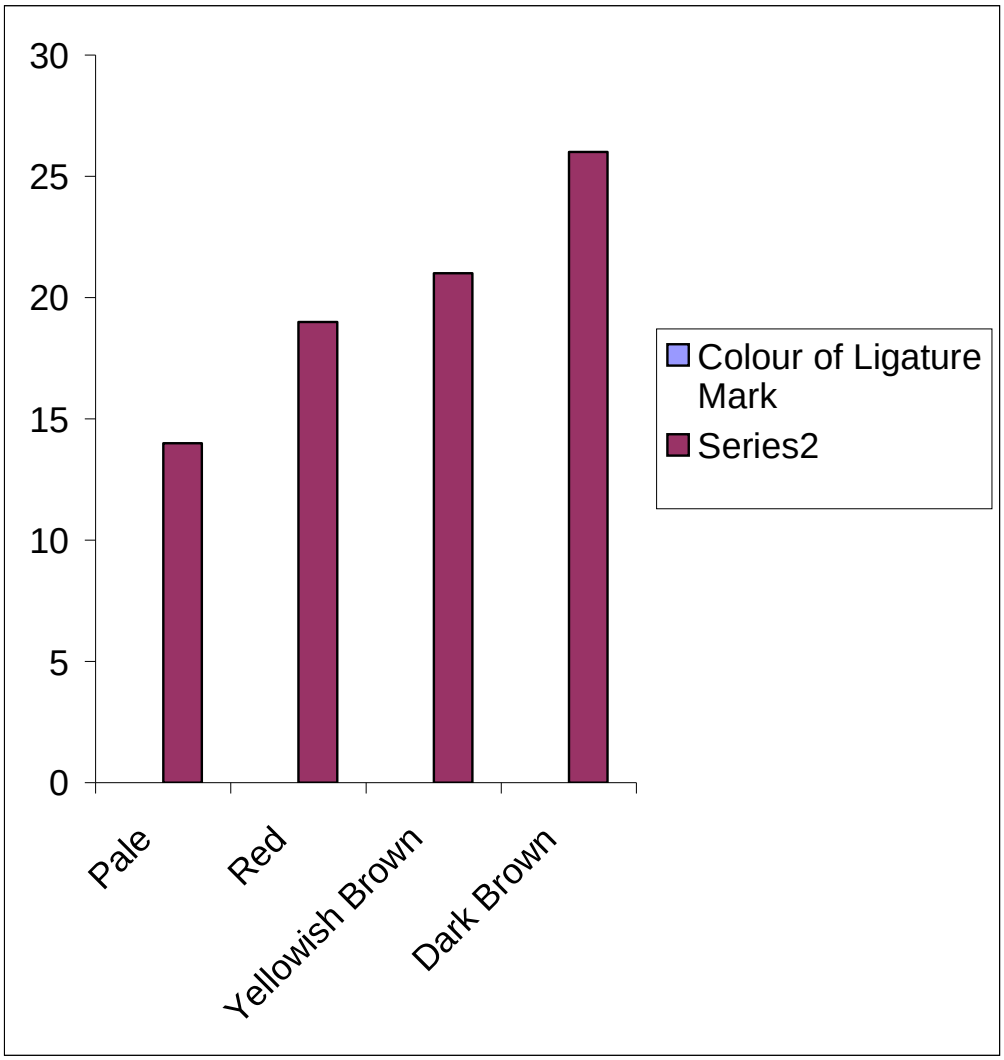

Distribution in the study population with respect to the ligature material used

TABLE 12 : Ligature Materials Used

Sl. No	Materials used	No. of victims	%

Create PDF files without this message by purchasing novaPDF printer (http://www.novapdf.com)

1	Soft	44	55
2	Hard	36	45
	Total	80	100

In the present study in 44 cases (55%) soft ligature material like lungi, duppatta, saree etc. were used and in 36 cases (45%) hard ligature material like nylone rope in 12 cases, electric cord in 3 cases, coir rope in 20 cases, plastic binder in 1 case.

Similar findings were observed in the studies conducted by G.A. Sunil Kumar Sharma,O.P.Murthy and T.D.Dogra[7],Jitendra .K. Balabantaray,[35] B.K. Sen Gupta.[15] Because the suicidee uses readily and easily available ligature material.

It is in contrast to the findings observed by Jonathan P. wyatt, Wyatt P.W.,Squires T.J.,andBusutill.A.[36],Feigin Gerald,[37] the reasons being usage of dogs lead, dressing gown cord, electric cable, suit case webbing, telephone cord, shoes strings, Bath robe belt etc. were used as ligature materials.

Fig 15 : Distribution in the study population with respect to the ligature materials used.

Create PDF files without this message by purchasing novaPDF printer (http://www.novapdf.com)

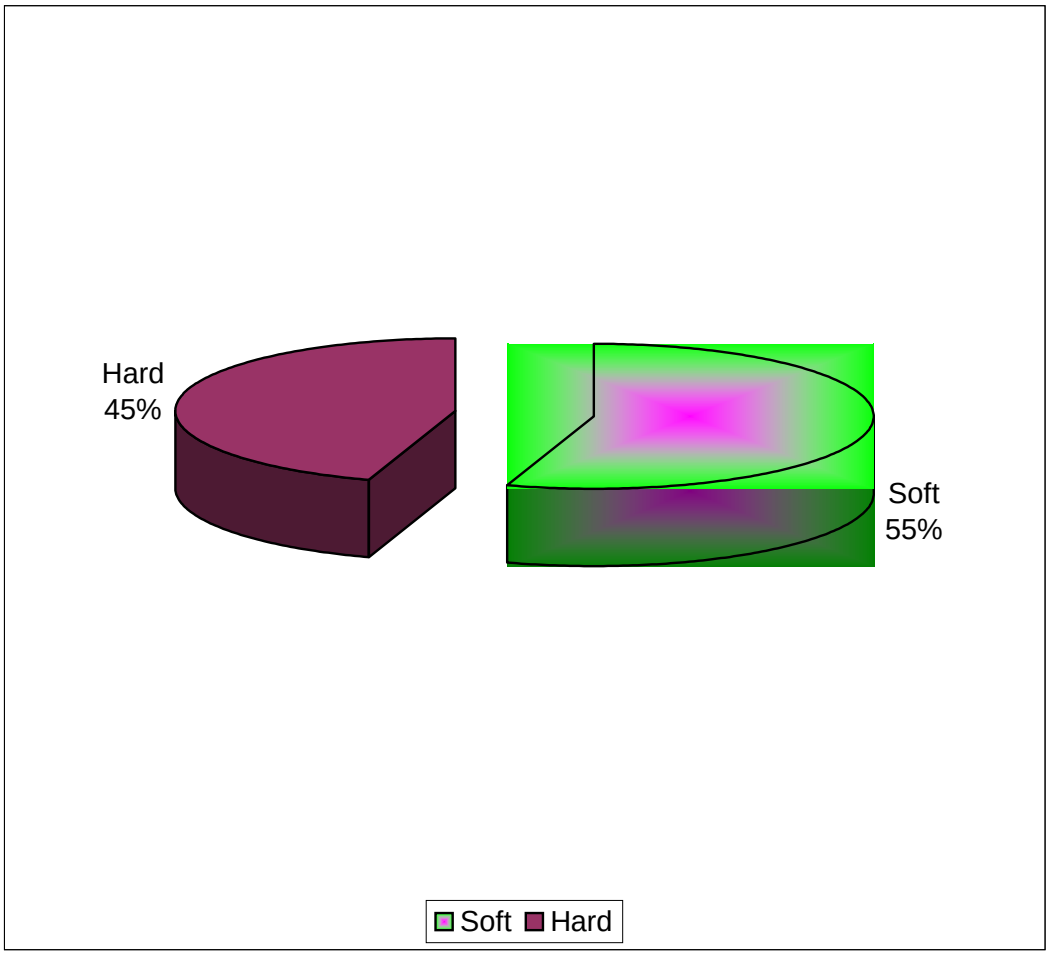

Distribution in the study population according to the position and type of the knot .

TABLE 13 : Position of the knot

Sl. No	Position of the Knot	No. of victims	%
1	Right occipital	23	28

Create PDF files without this message by purchasing novaPDF printer (http://www.novapdf.com)

2	Below the right ear	19	23
3	Left occipital	18	22
4	Occipital	14	18
5	Below the left ear	5	8
6	Below the chin	1	1
7	Others	0	0
	Total	80	100

Table 14 : Type of Knot

Sl. No	Type of knot	No. of victims	%
1	Slipping	44	55
2	Fixed	36	45
	Total	80	100

In the present study it is observed that in 23 cases (28%) the knot was in the right occipital region, in 19 cases (23%) it was below the right ear, in 18 cases (22%) it was in the left occipital region, in 14 cases (18%) occipital knot, in 5 cases (8%) below the left year and in 1 case (1%) below the chin. Right and left and occipital positioning of knot were considered as posterior hangings, knot marks on the left and right anterior aspect of the neck below the ears were considered anterior hangings.

In 44 cases (55%) running noose with a slipping knot were used and fixed knot in 36 cases (45%). Similar findings were observed in the studies conducted by Nicolic Slobodan, Micic Jelena, Atanasijevic Tatjana, Djolic Vesna, Djonic Danijela [13] ,Betz P. and Eisenmenger.w.[34] ,Jorn Simonson,[30] Jitendra K. Balabantaray.[35]

Fig 16 & 17 : Distribution in the study population according to the position and type of the knot

Create PDF files without this message by purchasing novaPDF printer (http://www.novapdf.com)

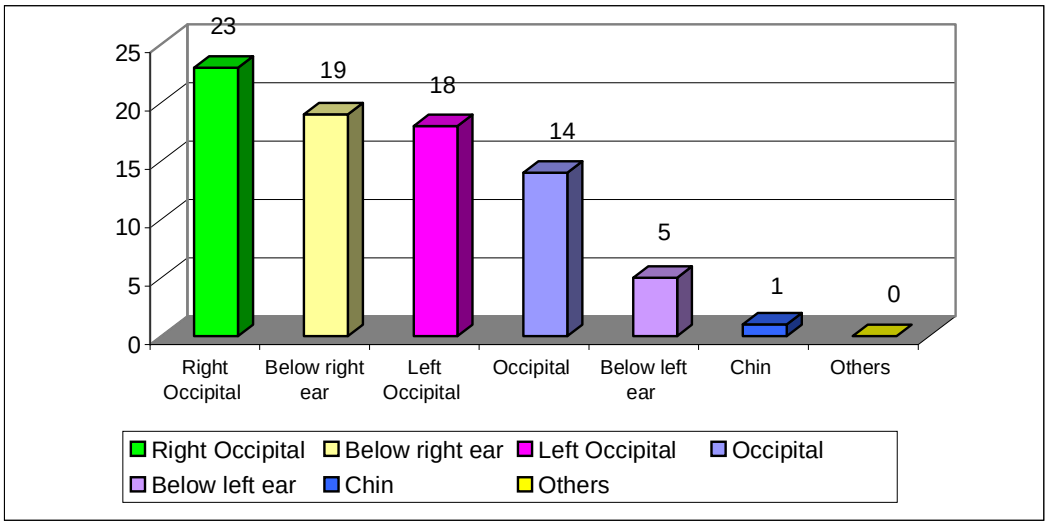

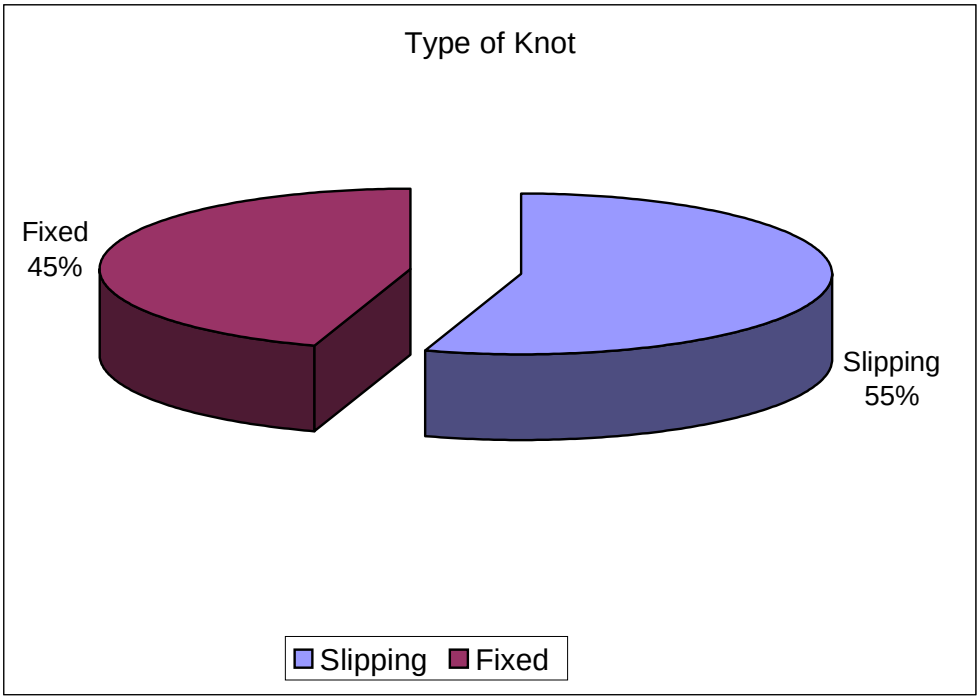

Distribution in the study population based on effusion of blood into the deep tissues of the neck.

Create PDF files without this message by purchasing novaPDF printer (http://www.novapdf.com)

TABLE 15 : Effusion of blood into the deep tissues of the neck

Sl. No	Effusion	No. of victims	%
1	Present	1	1
2	Absent	79	99
	Total	80	100

In the present study population it is observed that in 79 cases (99%) tissues beneath the ligature mark were pale and glistening with effusion of the blood seen in only 1 case. The reason for effusion in this case being the victim after tying the ligature around the neck took a long drop from the branch of a tree.

Similar findings were observed in the studies conducted by M.P. Sarangi,[32] A. Momonchand, Th.Meera Devi and L.Fimate[33],Nikolic Slobodan, Micic Jelena, Atanasijevic Tatjana, Djokic Vesna, Djonic Danijela.[13]

Fig 18 : Distribution in the study population based on effusion of blood into the deep tissues of the neck

Create PDF files without this message by purchasing novaPDF printer (http://www.novapdf.com)

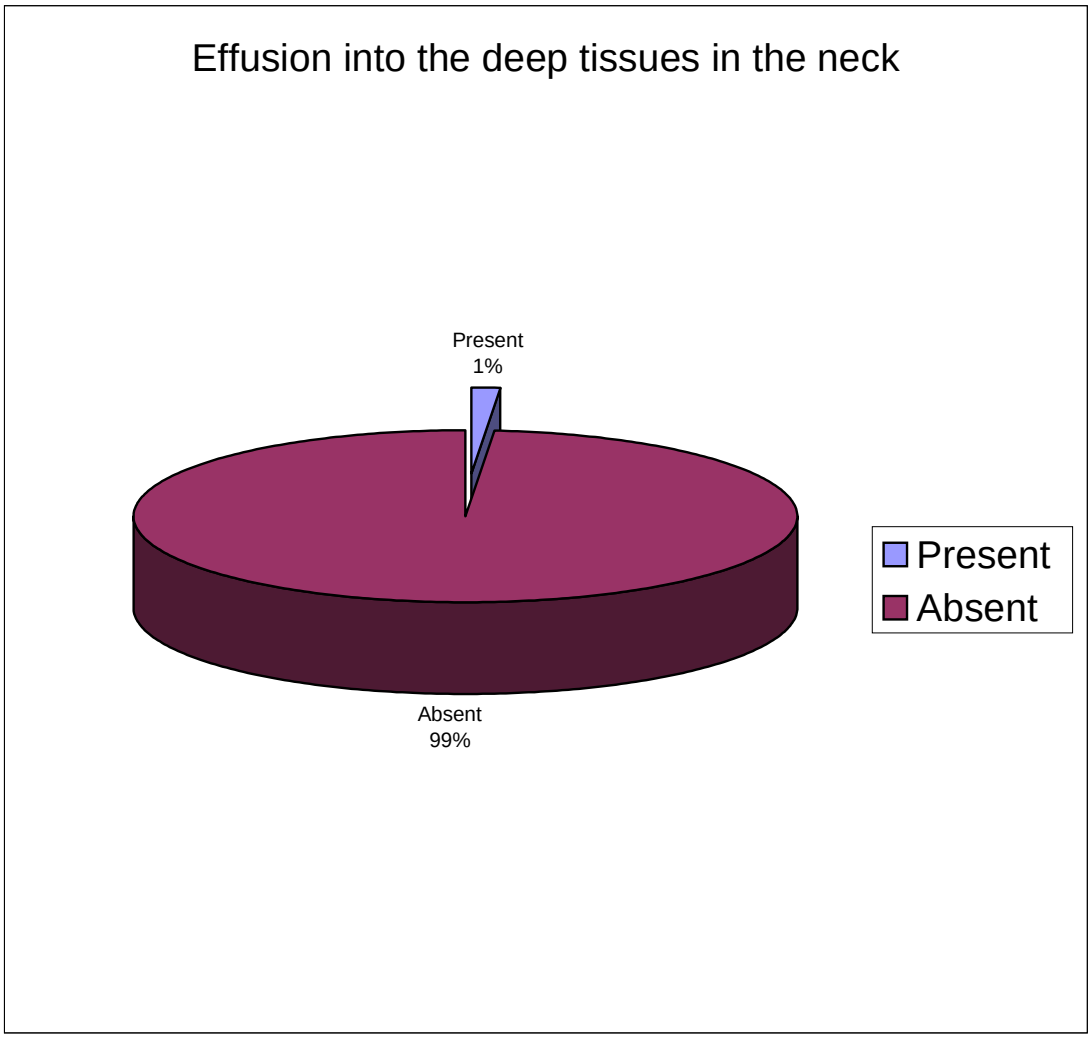

Distribution in the study population with respect to the fracture of thyroid cartilage and hyoid bone.

TABLE 16 : Fracture of thyroid cartilage

Sl. No	Fracture of thyroid cartilage	No. of victims	%
1	Present	3	4

Create PDF files without this message by purchasing novaPDF printer (http://www.novapdf.com)

2	Absent	77	96
	Total	80	100

Table 17 : Fracture of Hyoid bone

Sl. No	Fracture of Hyoid bone	No. of victims	%
1	Present	2	3
2	Absent	78	97
	Total	80	100

In the present study it is observed that in 77 cases (97%) there was no fracture the thyroid cartilage and only in 3 cases (3%) there was a fracture of the superior horn on the left side of the thyroid cartilage. The victims being in their 4th and 5th decades of life. the reasons being complete suspension of the victim, ossification increasing with the age after 30 years, pressure over the horns exerted on to the spine because of greater traction.

Similar findings were observed in the studies done by Nikolic Slobodan, Micic Jelena, Atanasijevic Tatjana,Djokic Vesna, Djonic Danijela.[13],Betz P.and Eisenmenger. S[34],Feigin Gerald,[37] Jitendra Balabantaray.[35] H. Green,James R.A.,Gilbert J.D.,and Byard R.W. [38],Ryk James,[27] Jorn Simonson,[30] Gary. P. Paparo.[22]

In the present study in 78 cases (98%) no fracture was detected and only in 2 cases (2%) showed fracture of the greater cornu on the right side of the hyoid bone. The age of the victim more than 60 years. The reason being the fracture increases with the age, seen commonly in typical and complete hanging, in cases of highest level of ligature mark on the back of the neck, increased duration of suspension and with a thin hard ligature material.

Create PDF files without this message by purchasing novaPDF printer (http://www.novapdf.com)

Similar findings were observed in the studies done by A. Momonchand, Th.Meera Devi and L.Fimate[33],Ryk James,[27] C.B. Jani and B.D.Guptha,[11] M.P. Sarangi,[32]Betz.P.andEisenmenger.S.[34],NikolicSlobodan,MicicJelena,Atanasijevic Tatjana,Djokic Vesna,Djonic Danijela.[13].,Feigin Gerald,[37] I. Morild,[26] Gary P. Paparo and Siegel.H.[22]

Create PDF files without this message by purchasing novaPDF printer (http://www.novapdf.com)

Fig 19 & 20 : Distribution in the study population with respect to the fracture of thyroid cartilage and hyoid bone.

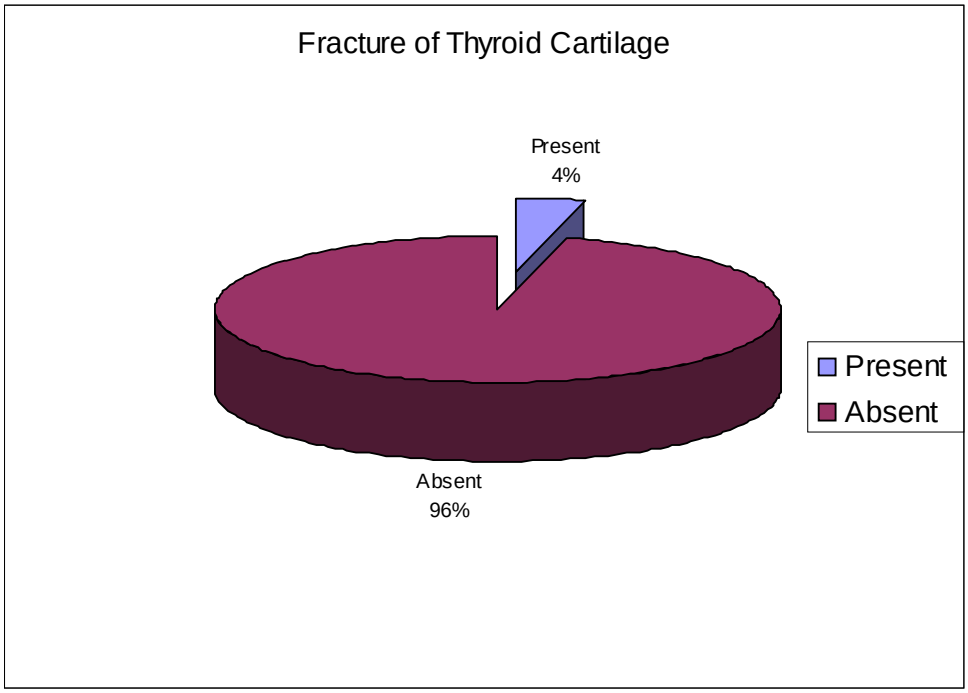

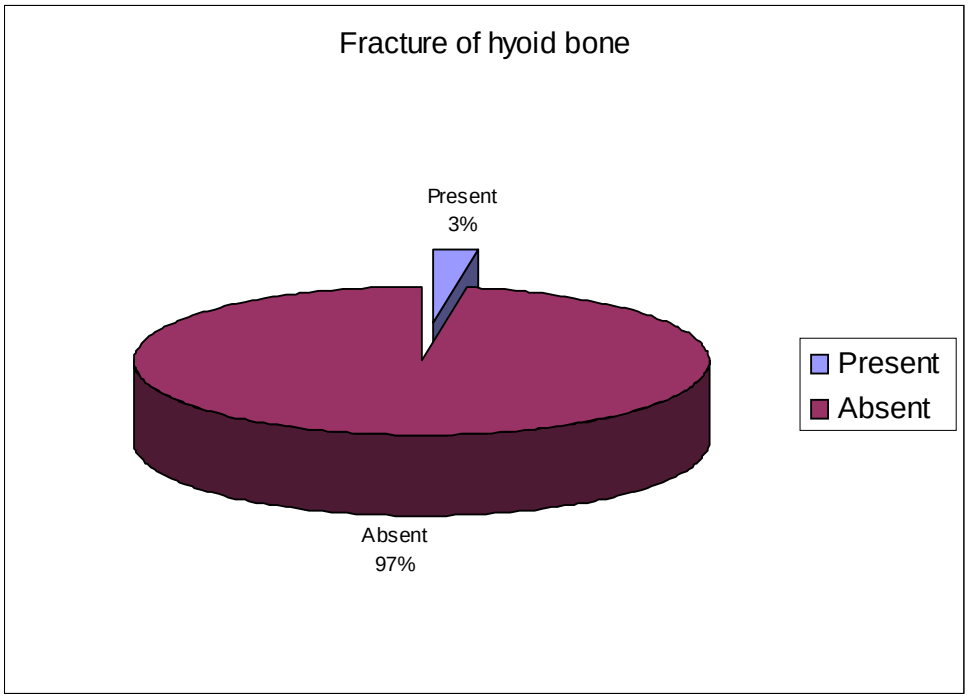

Create PDF files without this message by purchasing novaPDF printer (http://www.novapdf.com)



Plate No. 1 : Photograph shows a case of "complete hanging" with a long drop.



Plate No. 2 : Photograph shows a case of "partial hanging" (the deceased is in a kneeling position) .Note: Plastic Binder used as ligature material

Create PDF files without this message by purchasing novaPDF printer (http://www.novapdf.com)



Plate No. 3 : Photograph shows ligature mark only on the right side of the neck "Atypical ligature mark".



Plate No. 4 : Photographs showing the ligature mark encircling the neck – narrow, grooved "Typical ligature mark".

Create PDF files without this message by purchasing novaPDF printer (http://www.novapdf.com)



Plate No. 5 : Photograph showing a broad "Prominent and parchmentised mark" situated "Above the thyroid cartilage".



Plate No. 6 : Photograph showing the ligature mark which is "Over riding" the thyroid cartilage

Create PDF files without this message by purchasing novaPDF printer (http://www.novapdf.com)



Plate No. 7 : Photograph showing a "Faint ligature mark" situated "Below the level of thyroid cartilage".

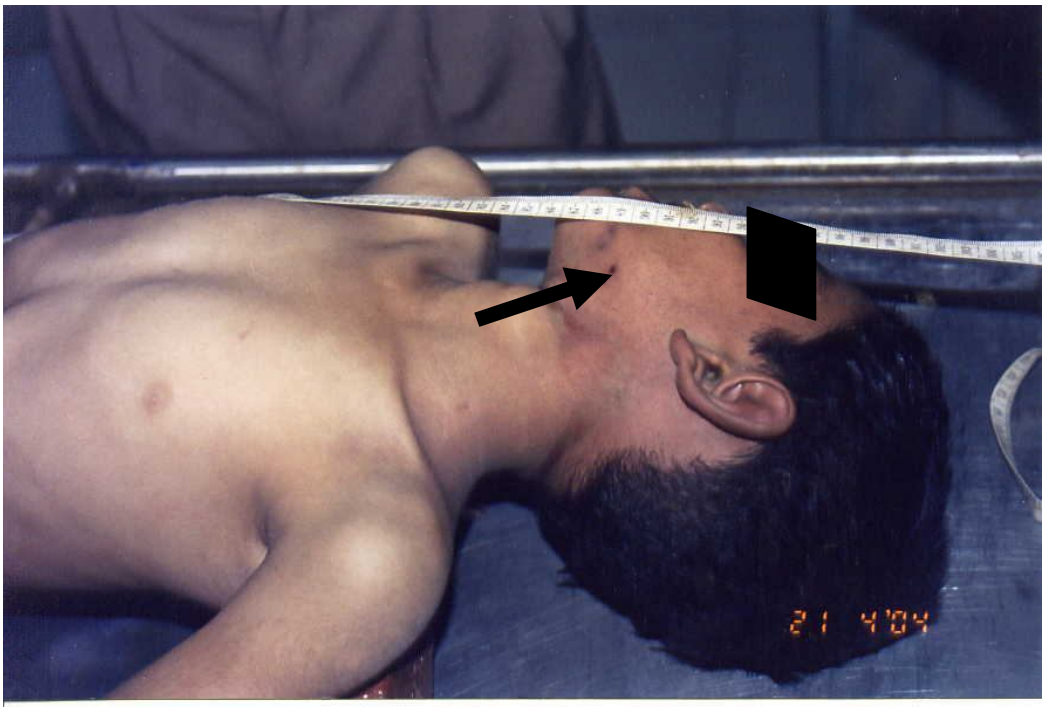

Plate No. 8 : Photograph showing "Periligature injury" – abrasion over the left angle of mandible.

Create PDF files without this message by purchasing novaPDF printer (http://www.novapdf.com)



Plate No. 9 : Photograph showing "Multiple ligature marks" with ligature material in situ and material being cut away from the knot. Note: Pattern of the ligature material reproduced over the skin.

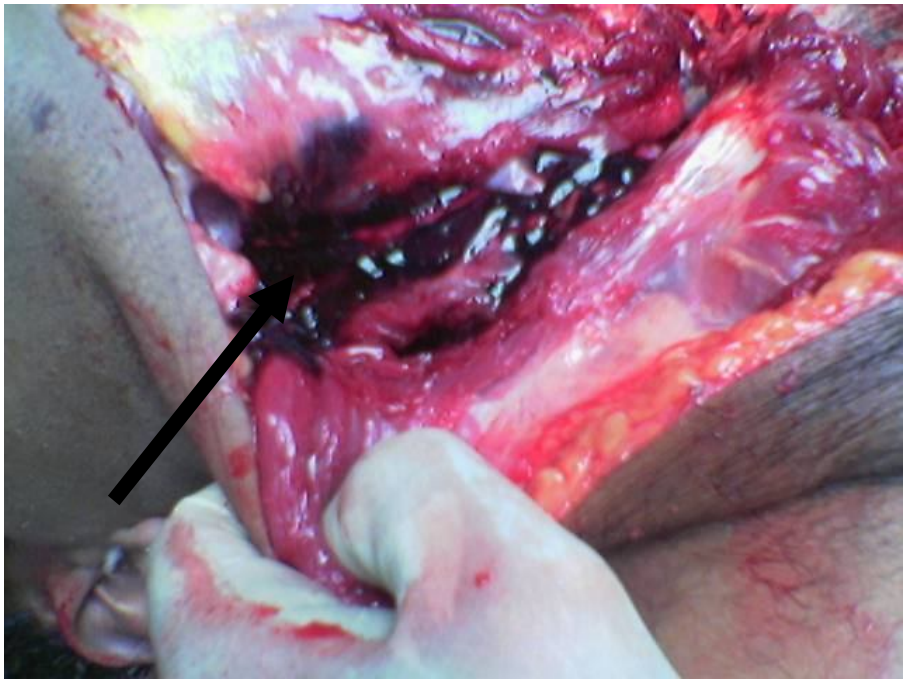

Plate No. 10 : Photograph showing "Extravasation" into the tissues over the right side of the neck in the case of long drop.

Create PDF files without this message by purchasing novaPDF printer (http://www.novapdf.com)

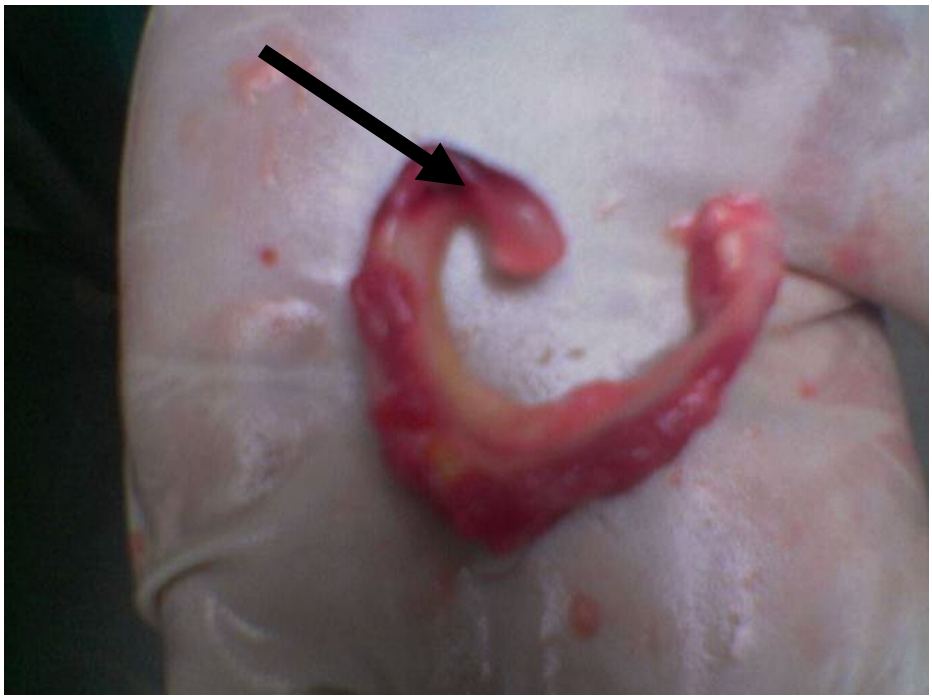

Plate No. 11: Photograph showing "Fracture of right horn of Hyoid bone" in an elderly individual.

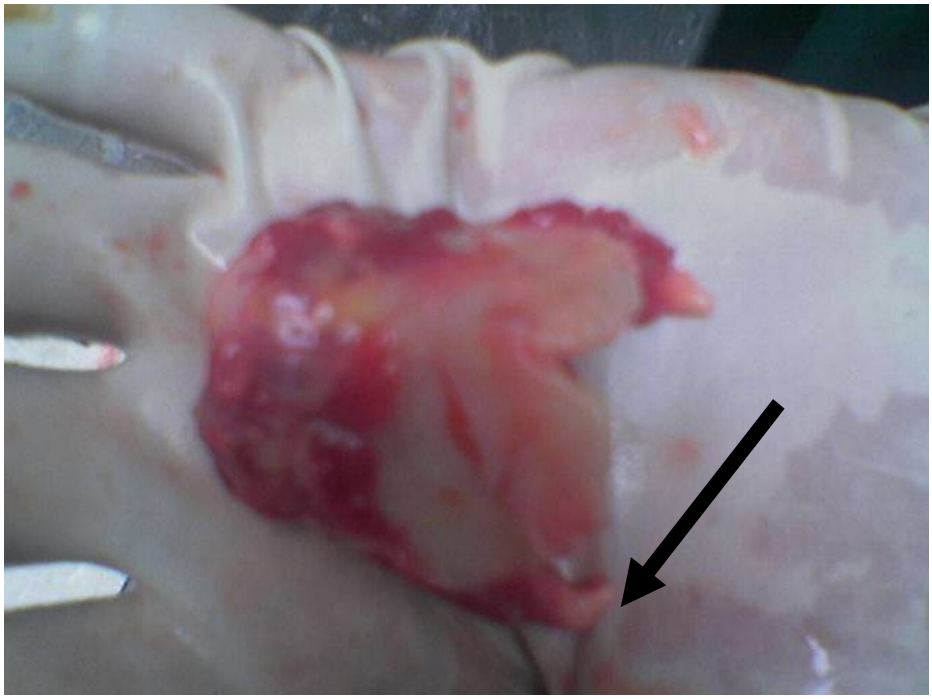

Plate No. 12 : Photograph showing "Fracture of left cornua of the thyroid cartilage" in a case with multiple rows of ligature applied around the neck

Create PDF files without this message by purchasing novaPDF printer (http://www.novapdf.com)

Photograph showing various types of ligature materials



Photo 13 : Hard : coir rope



Photo 14 : Plastic binder



Photo 15 : Soft : Cloth



Photo 16 : Nylon rope

Create PDF files without this message by purchasing novaPDF printer (http://www.novapdf.com)

CONCLUSION

A study on Ligature mark in cases of hanging among autopsies conducted at M.S.Ramaiah Medical college,Bangalore between 2004 and 2005 April concludes as follows:

Characteristic features of the ligature mark observed were:

- Atypical ligature marks with complete hanging outnumbered typical ligature mark with partial hanging.
- Single ligature mark above the level of thyroid cartilage with a breadth of 1to2cms is observed in the maximum number of cases.
- Periligature injuries including rope burns, ecchymoses and abrasions is observed in very few cases.
- Coarse ligature mark with parchmentisation is observed in the majority of the subjects with colour of the ligature mark ranging between yellowish brown to dark brown.
- Soft ligature materials were commonly employed with posterior knot positioning and the type of knot commonly employed being slipping knot.
- Hard and soft ligatures with increased duration of suspension(>5hrs)caused dark brown colour of the ligature mark with parchmentisation. Duration of suspension between 1to5hours with both hard and soft ligatures led to the formation of yellowish brown to dark brown colour of the ligature mark. In cases where the duration of suspension was less than 1hour a pale or faint red colour of the mark was observed.

Create PDF files without this message by purchasing novaPDF printer (http://www.novapdf.com)

- A distinct ligature mark furrow/groove of the width and pattern of the material used is observed in cases where a narrow and tough or hard ligature material is employed . Also in cases of complete hanging prominent ligature mark is observed. With softer and broader ligature materials a less distinct mark is observed. Ligature groove being deepest opposite the side of fixed knot is noted. A slip knot which caused the noose to tighten and squeeze through the full circumference of the neck caused a continuous ligature mark.
- Features of antemortem hanging i.e. dribbling of saliva mark, Le facie sympathique were noticed externally and in some cases the skin with ligature mark was sent for histopathological examination however the results were not conclusive regarding the nature of the ligature mark as antemortem or postmortem .
- All the deaths due to hanging studied were concluded as suicidal in manner based on the history, circumstantial evidence, examination of ligature material, ligature mark characters like a single, interrupted, oblique mark above the level of thyroid cartilage with slipping of the ligature mark, periligature injuries and other internal findings on dissection of the neck tissues .

Create PDF files without this message by purchasing novaPDF printer (http://www.novapdf.com)

SUMMARY

A study on ligature mark in cases of hanging among autopsies conducted at M.S.Ramaiah Medical college, Bangalore between April 2004 and April 2005 was done. The aims of this study were to study the pattern of ligature marks, study the factors responsible for the formation of ligature marks in relation to the material and correlating the ligature mark with the manner of death.

A sum total of 80cases were selected for this study. Detailed information regarding the deceased and the circumstances of death was collected from the police and relatives by a questionnaire. Standard autopsy technique was employed in all cases.

Maximum number of suicidal hangings occurred in the age group of 20 to 29 years(mean=24.5). Number of hanging deaths in the males were more than the female. Single ligature mark in an interrupted manner with varying degrees of colour changes corresponding to the duration of suspension and ligature material used were observed. Antemortem features of hanging like dribbling of saliva, abrasions, rope burns and ecchymoses around the ligature mark, transverse tears of the intima of carotids, asphyxial signs and Le facie sympathique helped in ascertaining the cause, nature and manner of death. Microscopic findings of ligature site skin after the histopathological examination were opined as keratinized epidermis, dermis showing focal aggregation of mononuclear cell infiltration including lymphocytes and congested vessels in the deeper dermis with melanin incontinence with an impression stating the antemortem ligature site reaction.

In a few cases the victims had resorted to committing suicide by hanging after consuming poison (Attempted dual methods).

Create PDF files without this message by purchasing novaPDF printer (http://www.novapdf.com)

LIMITATIONS OF THE STUDY

1. Study confined to a particular area.

2. Information regarding the deceased is based only on the history provided by police, relatives, panchanama, photograph of the scene of occurrence.

Create PDF files without this message by purchasing novaPDF printer (http://www.novapdf.com)

RECOMMENDATIONS

- In the present study, using the histopathological examination of the skin over the ligature mark to decide the antemortem or postmortem nature of the ligature mark was not of conclusive value. Hence this gives wide scope for other methods like enzyme histochemistry and other biochemical markers which could play a vital role in deciding the nature of the ligature mark as antemortem or postmortem.
- In cases of a faint or absent ligature mark using a cellophane tape over the area of the ligature mark on the neck and analyzing it under a comparative microscope with the material could collaborate with the ligature material.

From the medico legal point of view, it is recommended that in cases of deaths due to hanging the following protocol is necessary:

- Photograph of the scene of occurrence should include point of suspension.
- In fatal cases not to disturb the ligature material and release only the suspension point or cut the ligature material away from the site of knot.
- To always bring the material along with the body for correlation with the mark.
- Radiograph of the neck plays a vital role to appreciate the fractures of hyoid bone and thyroid cartilage.
- If necessary to visit the scene of occurrence.

Create PDF files without this message by purchasing novaPDF printer (http://www.novapdf.com)

BIBLIOGRAPHY

1. **Parikh C.K.** "Parikh's textbook of medical jurisprudence, Forensic Medicine and Toxicology for classrooms and courtrooms". 6th edition,CBS publishers and distributors,New Delhi;1999: 3.33-4.10.
2. **Gray's.** "Text Book of Human Anatomy." 33rd Edition, The bath press, ELBS; 1965: 1248-1260.
3. **Otto Sapphire**. "Autopsy Diagnosis and Technique". 4th Edition, Illinois : Hoeber Harper.
4. **Cox H.W.V. Bernard Knight, V.B. Salai, V.S. Sinha, M.L. Singhal.** "Medical Jurisprudence and Toxicology." 6th Edition,The law book company (p) Ltd; 1990 : 249-269.
5. **Subrahmanyam B.V.** "Modi's Medical Jurisprudence and Toxicology." 22nd edition Butterworths India, NewDelhi ;1999: 251-272.
6. **Vij Krishan.** "Textbook of Forensic Medicine and Toxicology." 2nd edition B.I.Churchill Livingstone, New Delhi; 2002: 242-263.
7. **G.A. Sunil Kumar sharma, O.P. Murthy, T.D.Dogra.** "Study of ligature marks in asphyxial deaths of hanging and strangulation". International Journal of Medical Toxicology and Legal Medicine 2002; 4(2):21-24.
8. **Pradeep Kumar G. Manoj Kumar Mohanty. Shanavaz Baipady.** "Rope Burns :A feature of Antemortem Hanging". Journal of Karnataka Medicolegal Society, 2002 ;11 (2): 25-26.
9. **Knight Bernard,"**Knight's Forensic Pathology**"** III Edition; 2004(15): 383 – 389.
10. **Pillay V.V.** "Textbook of Forensic Medicine." 14th Edition 2004; (13): 223 – 228.

Create PDF files without this message by purchasing novaPDF printer (http://www.novapdf.com)

11. **Jani C.B. and Gupta B.D**. "An autopsy study of parameters influencing injury to osteocartilaginous structures of neck in hanging". International Journal of Medical Toxicology & Legal Medicine 2002; 5(1): 4-7.
12. **Manoj Kumar Mohanty, Prateek Rastogi, Virendra Kumar, Shanavaz Manipady.** "Periligature injuries in Hanging." Journal of Clinical Forensic Medicine 2003;10(4): 255-258.
13. **Nikolic Slobodan, Micic Jelena, Atanasijevic Tatjana, Djokic Vesna, Djonic Danijela.** "Analysis of Neck Injuries in Hanging [Case Report]" The American Journal of Forensic Medicine and Pathology 2003; 24(2): 179-182.
14. **Mason J.K. and Purdue B. N.**. "The Pathology of Trauma." III Edition; 2004 (15) : 244-248.
15. **Sen Gupta B.K**. "Studies on 101 cases of Death due to Hanging". Journal of Indian Medical Academy, 1965; 45(3):135-139.
16. **Mant A. K.** "Taylor's Principles and practice of Medical Jurisprudence." 13th Edition, Churchill Livingstone Edinburgh; 1984: 303-319.
17. **Luke J.L.** "Asphyxial Deaths by Hanging in NewYork City,1964-1965." Journal of Forensic Science 1967;12(3):359-369.
18. **Polson C.J. and Gee D. J.** "The essentials of forensic medicine". 3rd edition, Oxford: Pergamon Press,1973: 370-339.
19. **Narayan Reddy K.S.** "Fracture of the Hyoid bone." Journal of the Indian academy of Forensic Medicine 1978; (1) : 7-15.
20. **Bowen D.A.LL.** "Hanging – A review". Forensic Science International 1982; 20 : 247-249.

Create PDF files without this message by purchasing novaPDF printer (http://www.novapdf.com)

21. **MASON J.K..** "Forensic Medicine for lawyers." 2nd edition, London Butterworths Publishers;1983: 130-132.
22. **Paparo G.P. and Siegel H.** "Neck markings and fractures in suicidal hangings." Forensic Science International 1984; 24:27-35.
23. **Davison A and Marshall T.K.** "Hanging in Northern Ireland-A Survey." Medicine Science and Law, 1986; 26(1): 23–28.
24. **Luke J.L., Reay D.T., Eisele J.W. and Bonnell H.J.** "Correlation of Circumstances with Pathological Findings in Asphyxial Deaths by Hanging: A Prospective Study of 61 cases from Seattle, WA". Journal of Forensic Sciences 1985; 30(4): 1140–1147.
25. **Elfawal M.A. and Awad O.A.** "Deaths from Hanging in the Eastern province of Saudi Arabia." Medicine Science and Law, 1994;34(4):307–312.
26. **Morild I.** "Fractures of neck structures in suicidal hanging". Medicine Science and Law. 1996; 36(1): 80-84.
27. **Ryk James and Paul Silcocks.** "Suicidal Hanging in Cardiff-A 15 Year Retrospective Study." Forensic Science International 1992; 56:167-175.
28. **Moore.L. & Byard R.W.** "Pathological findings in hanging and wedging deaths in infants and children." The American Journal of Forensic Medicine & Pathology, 1993; 14(4): 296-302.
29. **Jeanette Guarner.** "Suicide by Hanging" a Review of 56 cases, The American journal of Forensic Medicine and Pathology, 1987; 8(1): 23-25.
30. **Simonsen J.** "Patho-anatomic findings in neck structures in asphyxiation due to hanging: a survey of 80 cases". Forensic Science International 1988; 38:83-91.

Create PDF files without this message by purchasing novaPDF printer (http://www.novapdf.com)

31. **Cooke C.T, Cadden G.A & Hilton J.M.N.** "Unusual Hanging Deaths." The American Journal of Forensic Medicine & Pathology, 1988; 9(4): 277-282.
32. **Sarangi M.P.** "Ligature Mark/s- In Forensic Pathologist's Perspective." Journal of Forensic Medicine and Toxicology 1998; 15(1): 99-102.
33. **Momanchand A., Meera Devi Th., Fimate L.** "Violent asphyxial deaths in Imphal." Journal of Forensic Medicine and Toxicology, 1998; 15(1):60-64.
34. **Betz P. and Eisenmenger W.** "Frequency of throat-skeleton fractures in hanging". The American Journal of Forensic Medicine & Pathology 1996; 17(3): 191-193.
35. **Balabantaray J.K.** "Findings in Neck Structures in Asphyxiation due to Hanging." Journal of the Indian Academy of Forensic Medicine, 1998;20(4): 82-84.
36. **Wyatt JP, Wyatt PW, Squires TJ and Busuttil A.** "Hanging Deaths in Children." The American Journal of Forensic Medicine and Pathology 1998; 19(4): 343-346.
37. **Feigin G.** "Frequency of neck organ fractures in hanging". American Journal of Forensic Medicine & Pathology 1999; 20(2): 128-130.
38. **Green H., James R. A., Gilbert J. D. and Byard R. W.** "Fractures of the hyoid bone and laryngeal cartilages in suicidal hanging". Journal of Clinical Forensic Medicine 2000; 7(3): 123-126.
39. **Apurba Nandy.** "Principles of Forensic Medicine", 2nd Edition, New central Book agency (P) Ltd; 2000 : 315-321.
40. **Dixit P.G, Mohite P.M and Ambade V.N.** "Study of histopathological changes in thyroid, salivary gland and lymph nodes in hanging." Journal of Forensic Medicine and Toxicology, 2001; 18(2):1-4.

Create PDF files without this message by purchasing novaPDF printer (http://www.novapdf.com)

41. **Varghese.P.S.** "Frequency of Fracture of hyoid bone and Thyroid cartilage in cases of Hanging" unpublished MD Dissertation submitted to the RGUHS, 2001. Personal communication.

42. **Deepak H.D.** "Pattern of Hyoid Bone Fractures in Deaths due to Pressure on the neck" unpublished MD Dissertation submitted to the RGUHS, 2005. Personal communication.

Create PDF files without this message by purchasing novaPDF printer (http://www.novapdf.com)

ANNEXURE I

QUESTIONNAIRE ON

STUDY OF LIGATURE MARK IN CASES OF HANGING

Information furnished by the Police /Relatives :

Name : Place of Death : Residence / Work place / Outside

Age : Date and place of death :

Sex :

Partial / Complete. Height of Suspension :

Hanging Type:

Typical / Atypical. Duration of Suspension :

Ligature Mark :

a. Number of ligature Marks : One / Two / Three / Nil.

b. Level of Ligature Mark : Above the thyroid cartilage.

Overriding thyroid cartilage.

Below the thyroid cartilage .

c. Direction of the Ligature Mark :

d. Length and Breath :

e. Relation to local landmark :

f. Continuous or interrupted

g. Impression of Ligature Mark : Faint / Prominent .

h. Slipping of Ligature Mark : Present / Absent .

i. Rope burns : Present / Absent .

j. Abrasion, contusion, nail marks

Create PDF files without this message by purchasing novaPDF printer (http://www.novapdf.com)

Or other periligature injuries : Present / Absent .

k. Texture of ligature Mark : Rough / Smooth / dry.

l. Parchmentisation : Present / Absent .

m. Colour of Ligature Mark : Pale / Reddish / Yellowish Brown / Dark Brown .

n. Extravasation of Blood at the Margin : Present / Absent.

o. P.M. Staining on the upper border of Ligature Mark : Present / Absent.

Ligature Materials : Saree / Dupatta / Towel / Lungi / Rope / Others.

Length of Ligature Materials :

Position of the Knot : Occipital / Rt occipital / Lt occipital / Chin /Below Right ear / Below left ear, Others.

Type of Knot : Slipping / Fixed / Unknown .

External Appearances :

a. Cyanosis : Present / Absent .

b. Petechial Haemorrhages : Present / Absent .

c. Sub – conjunctival Haemorrhages : Present / Absent .

d. Dribbling of Saliva Mark : Present / Absent .

e. Discharge of Semen / Faeces : Present / Absent .

f. Tongue bitten / Protruded : Present / Absent .

g. Clenching of Fist : : Present / Absent .

Create PDF files without this message by purchasing novaPDF printer (http://www.novapdf.com)

Internal Injuries :

Tissue underneath ligature Mark :

a. Pale : Yes / No .

b. Glistening white : Yes / No .

c. Contusion of deep tissues in neck : Present / Absent.

Thyroid cartilage : Fractured / Intact.

Other Laryngeal cartilages : Fractured / Intact .

Hyoid bone : Fractured / Intact .

Cause of Death : Hanging / Others .

Manner of Death : Suicidal / Accidental / Undecided.

Create PDF files without this message by purchasing novaPDF printer (http://www.novapdf.com)

ANNEXURE II

M.S. RAMAIAH HOSPITALS

(MSRMTH/MSRIC/MSRINU)

M. S. R. Nagar, M.S.R.I.T.Post, Bangalore –560054.
Tel: 91-80-3608888/3608961/3606524/3606545; Fax:91-80-3601924;
E-mail: msrhospitals @ vsln.com.

Name of Patient: S. Suryanarayan Date: 4/3/05 Patient .No: PM.No.110/05 dt.23/2/05
Treating Doctor: Age: 48 Years HPE.MLC.18/05
Dept.: Forensic Medicine Sex: Male Ward

Specimen received on: 2/3/05
Nature of Specimen: Skin.

MACROSCOPY: Specimen of skin covered soft tissue bit measuring 1.5x1cms. Ligature mark seen over the external surface. Cut section – Grey white.
A- Normal, B- from ligature mark

MICROSCOPY: Sections A from the normal area shows skin with epidermis. The dermis shows foci of mononuclear cell infiltration.
Sections B shows skin with dermis and epidermis. The epidermis is lined by stratified squamous epithelium with focal ulceration. Subepithelium shows disruption of the fibrocollagenous tissue, edema and congested blood vessels.

IMPRESSION: Skin – Features are consistent with ligature site reaction.

4/3/05
PATHOLOGIST.

for PROF. & HEAD, DEPT. OF PATHOLOGY
M.S. Ramaiah Medical College
BANGALORE-560 054

Create PDF files without this message by purchasing novaPDF printer (http://www.novapdf.com)

STUDY OF LIGATURE MARK IN CASES OF HANGING

by

Dr. K. ASHWINI NARAYAN

Dissertation submitted to
Rajiv Gandhi University of Health Sciences, Bangalore, Karnataka

In partial fulfillment of the University Regulations for the award of

M.D
In

FORENSIC MEDICINE

Under the Guidance of
Dr. Y.P. GIRISH CHANDRA
Associate Professor, Dept. of Forensic Medicine



Department of Forensic Medicine
M.S.Ramaiah Medical College and Teaching Hospital
Bangalore

2003 – 2006

Create PDF files without this message by purchasing novaPDF printer (http://www.novapdf.com)

RAJIV GANDHI UNIVERSITY OF HEALTH SCIENCES

DECLARATION BY THE CANDIDATE

I hereby declare that this dissertation/thesis entitled **"STUDY OF LIGATURE MARK IN CASES OF HANGING"** is a bonafide and genuine research work carried out by me under the guidance of **Dr. Y.P. Girish Chandra, MD. Associate Professor**, Department of Forensic Medicine, and Co-Guide **Dr. S. Harish MD, DFM** Prof. And H.O.D. Dept. of Forensic Medicine, M.S.Ramaiah Medical College.

Date :
Place:

Dr. K. Ashwini Narayan

Create PDF files without this message by purchasing novaPDF printer (http://www.novapdf.com)

CERTIFICATE BY THE GUIDE

This is to certify that the dissertation entitled **"STUDY OF LIGATURE MARK IN CASES OF HANGING"** is a bonafide research work done by **Dr. K. Ashwini Narayan,** under my direct guidance and supervision in the Department of Forensic Medicine ,M. S. Ramaiah Medical College, Bangalore in partial fulfillment of the requirement for the degree of MD in Forensic Medicine.

Date:
Place:

Dr. Y.P. GIRISH CHANDRA
Associate Professor
Department of Forensic Medicine
M.S.Ramaiah Medical College.

Create PDF files without this message by purchasing novaPDF printer (http://www.novapdf.com)

CERTIFICATE BY THE CO- GUIDE

This is to certify that the dissertation entitled **"STUDY OF LIGATURE MARK IN CASES OF HANGING"** is a bonafide research work done by **Dr. K. Ashwini Narayan,** under the direct guidance of Dr. Y.P.Girish Chandra, Associate Professor., Department of Forensic Medicine, M.S.Ramaiah Medical College, Bangalore in partial fulfillment of the requirement for the degree of MD in Forensic Medicine.

Date:
Place:

Dr. S. HARISH
Professor and H.O.D.
Department of Forensic Medicine
M.S.Ramaiah Medical College.

Create PDF files without this message by purchasing novaPDF printer (http://www.novapdf.com)

ENDORSEMENT BY THE HOD, PRINCIPAL/HEAD OF THE INSTITUTION

This is to certify that the dissertation entitled **"STUDY OF LIGATURE MARK IN CASES OF HANGING"** is a bonafide research work done by **Dr. K. Ashwini Narayan**, under the guidance of **Dr. Y.P. Girish Chandra, Associate Professor**, Department of Forensic Medicine, M.S.Ramaiah Medical College, Bangalore.

Dr. S. HARISH
Prof. & H.O.D
Department of Forensic Medicine
M.S.Ramaiah Medical College

Date:
Place:

Dr. S. Kumar
Principal
M.S.Ramaiah Medical College

Date:
Place:

Create PDF files without this message by purchasing novaPDF printer (http://www.novapdf.com)

COPYRIGHT

DECLARATION BY THE CANDIDATE

I hereby declare that the Rajiv Gandhi University of Health Sciences, Karnataka shall have the rights to preserve, use and disseminate this dissertation / thesis in print or electronic format for academic / research purpose.

Date:
Place:

Dr. K. Ashwini Narayan

© Rajiv Gandhi University of Health Sciences, Karnataka

Create PDF files without this message by purchasing novaPDF printer (http://www.novapdf.com)

ACKNOWLEDGEMENT

I find inadequate to express my deep sense of gratitude to Dr.Y.P. GIRISH CHANDRA, my Guide and Associate Professor, for his devoted, kind and keen interest, encouragement, suggestions and able guidance throughout my study, amidst his busy schedule.

It has been a great privilege and pleasure to have worked under Prof. Dr.S.HARISH, my Co-Guide, Professor and Head of the department. The present work would not have been possible without his meticulous attention, sincere criticism and untiring help. I respectfully acknowledge him for his valuable guidance and support at every stage of my work.

I respectfully acknowledge the guidance and supervision accorded by my honorable teachers Dr.M.G.Shivaramu Associate Professor, Dr.J.Kiran Associate Professor, Dr.T.Padmanabha Assistant Professor, Dr.S.Praveen Lecturer, Dr.Rajesh.M Lecturer for their help and advice, who have added luster to this dissertation work. I also thank the staff of pathology department of M.S.Ramaiah Medical College for their services.

My sincere thanks to my colleagues, Dr.Avishek Kumar, Dr.Deepak D'Souza, Dr.Pradeep K Saralaya, Dr.Venkataraghava, Dr.Naveen Kumar, Dr.Sanjay Sukumar and Dr.Satish, Dr. Basappa and Dr. Vasudev for their co-operation. I express my gratitude to my parents and wife for their encouragement and support.

I am also obliged to the police personnel, mortuary staff and relatives of the deceased. Finally I bow my head to pay my obeisance to all the deceased for having been the source of data collection.

Dr.Ashwini Narayan

Create PDF files without this message by purchasing novaPDF printer (http://www.novapdf.com)

TABLE OF CONTENTS

SL. NO	CONTENTS	PAGE No
1.	INTRODUCTION	1-3
2.	AIMS AND OBJECTIVES	4
3.	REVIEW OF LITERATURE	5-29
4.	MATERIAL AND METHODS	30-39
5.	RESULTS AND DISCUSSION	40-66
6.	CONCLUSION AND SUMMARY	67-69
7.	LIMITATIONS AND RECOMMENDATIONS	70-71
8.	BIBLIOGRAPHY	72-74
9.	ANNEXURES	76-80

Create PDF files without this message by purchasing novaPDF printer (http://www.novapdf.com)

LIST OF TABLES

SL. NO	TABLES	PAGE NO.
1.	Age distribution in the study population	40
2.	Sex distribution in the study population	40
3.	Distribution in the study population according to the type of hanging (Suspension)	42
4.	Distribution in the study population according to the type of hanging (Ligature Mark)	42
5.	Distribution among the study population with respect to multiplicity of ligature mark	44
6.	Distribution among the study population according to the level of ligature mark	46
7.	Distribution in the study population according to the breadth of the ligature mark	48
8.	Distribution in the study population with respect to character of the ligature mark	50
9.	Distribution among the study population according to the Periligature injuries.	52
10.	Distribution in the study population with respect to the texture and parchmentisation of the ligature mark	54
11.	Distribution in the study population according to the colour of ligature mark	56

Create PDF files without this message by purchasing novaPDF printer (http://www.novapdf.com)

12.	Distribution in the study population with respect to the ligature material used	58
13.	Distribution in the study population according to the position of the knot	60
14.	Distribution in the study population according to the type of the knot	60
15.	Distribution in the study population based on effusion of blood into the deep tissues of the neck.	62
16.	Distribution in the study population with respect to the fracture of thyroid cartilage.	64
17.	Distribution in the study population with respect to the fracture of hyoid bone.	64

Create PDF files without this message by purchasing novaPDF printer (http://www.novapdf.com)

LIST OF FIGURES

SL. NO	FIGURES	Page No.
1.	Bar graph showing age distribution in the study population	41
2.	Pie chart showing sex distribution in the study population	41
3.	Pie chart showing distribution in the study population according to the type of hanging (suspension)	43
4.	Pie chart showing distribution in the study population according to the type of hanging (ligature mark)	43
5.	Bar graph showing distribution in the study population with respect to multiplicity of ligature mark. (number of ligature marks)	45
6.	Pie chart showing distribution in the study population according to the level of ligature mark	47
7.	Pie chart showing distribution in the study population according to the breadth of ligature mark	49
8, 9.	Pie chart showing distribution in the study population with respect to character of the ligature mark	51
10, 11	Pie chart showing distribution in the study population according to the periligature injuries.	53
12, 13	Pie chart showing distribution in the study population with respect to the texture and parchmentisation of the ligature mark	55

Create PDF files without this message by purchasing novaPDF printer (http://www.novapdf.com)

14.	Bar graph showing distribution in the study population according to the colour of the ligature mark	57
15.	Pie chart showing distribution in the study population with respect to the ligature materials used.	59
16.	Bar graph showing distribution in the study population according to the position of the knot	61
17.	Pie chart showing distribution in the study population according to the type of the knot	61
18.	Pie chart showing distribution in the study population based on effusion of blood into the deep tissues of the neck	63
19, 20	Pie charts showing distribution in the study population with respect to the fracture of thyroid cartilage and hyoid bone.	66

Create PDF files without this message by purchasing novaPDF printer (http://www.novapdf.com)

LIST OF PLATES

SL. NO	PLATES	Page No.
1.	Plate 1 : Photograph shows a case of "complete hanging" with a long drop.	33
2.	Plate 2 : Photograph shows a case of "partial hanging" (the deceased is in a kneeling position)	33
3.	Plate 3 : Photograph shows ligature mark only on the right side of the neck "Atypical ligature mark".	34
4.	Plate 4 : Photographs showing the ligature mark encircling the neck – narrow, grooved "Typical ligature mark".	34
5.	Plate 5 : Photograph showing a broad "Prominent and parchmentised mark" situated "Above the thyroid cartilage".	35
6.	Plate 6 : Photograph showing the ligature mark which is "Over riding" the thyroid cartilage	35
7.	Plate 7 : Photograph showing a "Faint ligature mark" situated "Below the level of thyroid cartilage".	36
8.	Plate 8 : Photograph showing "Periligature injury" – abrasion over the left angle of mandible.	36
9.	Plate 9 : Photograph showing "Multiple ligature marks" with ligature material in situ	37

Create PDF files without this message by purchasing novaPDF printer (http://www.novapdf.com)

10.	Plate 10 : Photograph showing “Extravasation” into the tissues over the right side of the neck in the case of long drop.	37
11.	Plate 11: Photograph showing “Fracture of right horn of Hyoid bone” in an elderly individual.	38
12.	Plate 12 : Photograph showing “Fracture of left cornua of the thyroid cartilage” in a case with multiple rows of ligature applied around the neck	38
13.	Photograph showing various types of ligature materials	39

Create PDF files without this message by purchasing novaPDF printer (http://www.novapdf.com)

INTRODUCTION

Violent asphyxial deaths is one of the most important cause for unnatural deaths amongst which hanging and strangulation are commonly encountered in day to day autopsy.

Hanging is that form of asphyxia, which is caused by suspension of the body by a ligature around the neck, the constricting force being the weight of the body.

The important external sign is the ligature mark, which is a pressure mark/abrasion on the neck at the site of the ligature. It appears as a groove. However atypical ligature marks are encountered routinely. Character of the ligature mark depends upon the nature of the ligature, body weight, length of time the body has remained suspended and number of turns of the ligature round the neck. The course of the ligature mark depends on whether a fixed or running noose has been used.

In complete hanging ,the ligature mark is situated above the level of thyroid cartilage between the larynx and chin. It is directed obliquely upwards along the line of the mandible and reaches the mastoid processes behind the ears. It is sometimes absent at the back where the two limbs of the noose stretch upwards towards the knot, the mark is better seen on the front and sides of the neck than on the nape where firm muscular tissue and scalp hair intervene.

Instead of an obliquely directed ligature mark, this may be circular if the material is tied round the neck. Sometimes there may be double ligature marks. This may be due to slippage of the ligature .If the ligature is tied two or three times round the neck and then goes upto the knot, in addition to encircling marks, there is an inverted V shaped mark. This is confusing to those not familiar with the combination of such marks who may associate the lower (horizontal) marks with ligature

Create PDF files without this message by purchasing novaPDF printer (http://www.novapdf.com)

strangulation and the upper one with hanging. The ligature mark may be faint if a soft material is used or if the ligature is cut immediately after the hanging.

It is easy to diagnose hanging when one finds the classical features. However all features are seldom present together. The application of pressure on the neck often results in findings, which could be local and/or generalized. The extent and type of findings can often be correlated with the specific circumstances and mechanisms of its causation. While such correlations may not be perfect always, yet the scientific forensic investigation forms an important part of the overall investigation in the event of deaths from pressure on the neck.

Deaths resulting from hanging show pathological findings, amongst which the ligature mark in the neck is considered to be decisive. [1]

Create PDF files without this message by purchasing novaPDF printer (http://www.novapdf.com)

NEED FOR THE STUDY

In every human being death is inevitable. Some people for reasons not clearly understood choose to end their own lives. Motive for such deaths may be socioeconomic, psychological factors or health problems.

In the present day such deaths leaves puzzles like manner of death whether suicidal or homicidal. Commonest modes of committing suicides are by hanging or consumption of poison or drowning. In hanging the appreciation of external signs particularly ligature mark plays a vital role. Hence a proper observation and study of ligature mark which is the characteristic hallmark of hanging needs greater emphasis.

Apart from the typical ligature mark atypical ligature marks are also seen leading to lot of curiosity in the mind of autopsy surgeon during the day-to-day postmortem examination. Hence a prompt and sincere attempt is being made to study the correlation between the ligature mark and the material producing it along with the relation between external and internal features in the neck in cases of hanging.

Create PDF files without this message by purchasing novaPDF printer (http://www.novapdf.com)

AIMS & OBJECTIVES OF THE STUDY

1. To study the pattern of ligature marks.

2. To study the factors that contribute for the formation of ligature marks.

3. To correlate the ligature mark with the manner of death.

Thus Ligature mark/s, if can be the only finding to successfully distinguish a death resulting from hanging or otherwise, has been examined from medico-legal acumen.

Create PDF files without this message by purchasing novaPDF printer (http://www.novapdf.com)

REVIEW OF LITERATURE

Applied Anatomy of the Neck

The side of the neck is quadrilateral and divided into anterior and posterior triangles. **The anterior triangle of the neck**: This region includes the area from chin to sternum and the structures encountered are skin, superficial fascia, platysma, anterior jugular veins, submental lymph nodes, deep fascia above the hyoid bone, submandibular salivary gland, between the hyoid bone and cricoid cartilage, sternomastoid muscles, structures lying above hyoid bone are mylohyoid muscle overlapped by anterior belly of digastric muscle, submandibular salivary gland, mylohyoid nerve and vessels, submental branch of facial artery, hyoglossus muscle, stylohyoid muscle and hypoglossal nerve. Structures below hyoid bone: a) Infrahyoid muscles. b) Thyroid gland c) Larynx and trachea d) Oesophagus posteriorly. Further the anterior triangle of neck is subdivided into **a) Submental triangle b) Digastric triangle c) Carotid triangle.Posterior triangle of the neck:** Contains platysma, external jugular, posterior external jugular vein, part of supraclavicular, great auricular, lesser occipital nerve and occipital, transverse cervical, suprascapular arteries.

Back of the neck: Contains Ligamentum nuchae and muscles namely trapezius and latissimus dorsi, levator scapulae rhomboids, erector spinae occipital and deep cervical artery, third part of vertebral artery.[2]

Dissection techniques

For bloodless dissection of the neck first the thoracoabdominal contents and the brain is removed before proceeding to the neck dissection. A block 12 to 20cm high should be placed under the shoulders to allow the head to fall back thus the neck is extended. The skin is held with a tooth forceps and incision started from chin in the

Create PDF files without this message by purchasing novaPDF printer (http://www.novapdf.com)

center and carried down till the pubis, subcutaneous dissection carried to the lower border of lower jaw, laterally on the sides of neck and clavicle. Deep cervical fascia is reflected from cervical muscles and strap muscles of the neck are exposed, inspected and reflected on each side. Thyroid gland and carotid sheath is freed by blunt dissection. Larynx, trachea, pharynx and oesophagus mobilized and pulled away from the prevertebral tissue by blunt dissection. The mouth is opened and the tip of tongue pushed upwards and backwards. The knife is inserted under the chin through the floor of the mouth cut along the sides of the mandible to the angle of the mandible dividing the neck muscles attached to the lower jaw. At the angle of mandible blade is turned inwards and tongue is pushed down under the mandibular arch, soft palate is cut to include uvula and tonsils with the tongue and the neck organs removed enmasse. Posteriorly the attachments are freed from the prevertebral muscles on the anterior surface of the cervical vertebra till the jugular notch and the great vessels are divided in the neck.[3]

Ligature Marks in hanging :

The description of the ligature mark includes its position, direction, continuous or interrupted, colour, depth, periligature injuries, ligature patterns areas of the neck involved and its relation to the local landmarks. When the loop is arranged with fixed knot inverted V with its apex corresponding to the site of knot is produced, a fixed loop with a single knot in the midline at the back of the head produces mark on both the sides of neck and is directed obliquely upwards. Fixed loop with the knot in the region of one ear produces different ligature marks. On the side of the knot mark it is oblique and on the opposite side it is transverse. With a running noose a transverse mark may be produced with resemblance to strangulation. In partial hanging horizontal mark may be produced. Fixed loop with a single knot below the chin in the mid line

Create PDF files without this message by purchasing novaPDF printer (http://www.novapdf.com)

produces a mark, which is seen on the back and both the sides of the neck and is directed obliquely towards the knot.

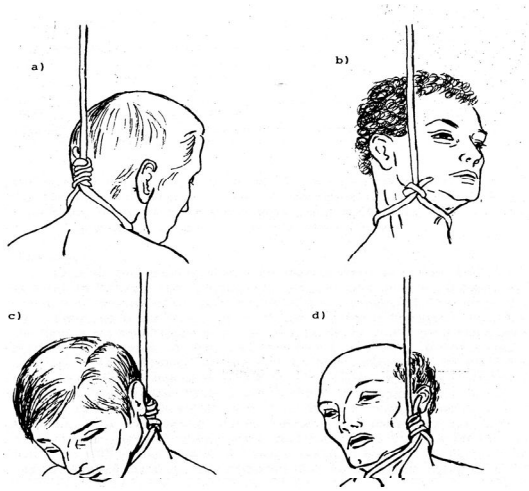

A retrospective study of 101 cases of suicidal hanging deaths at Calcutta in 1965 showed complete hanging in 88 cases and partial hanging in 10 cases. Ligature mark was single in all but one case. In that unique case, ligature mark was in two rows. In most of the cases the knot was slipping type. In about 20% of the cases with the ligature material brought with dead body, the knot was fixed. The site of knot was found in the right side of neck in 53 cases, in the left side of neck in 39, in back of neck in 12, and in chin in 4 cases. Sari was used as ligature material in 20 cases, dhoti in 20, ropes in 41, napkin in 12, wrapper in 3, electric wire in 1, lungi in 2, belt in 1, and chadder in 1. In 73 cases, the ligature mark was above thyroid cartilage. In 27 cases, it was over upper part of thyroid cartilage and in 1 case, it was below the thyroid cartilage. No fracture or dislocation of cervical vertebrae was found. Hyoid bone and larynx were found intact in all cases.[4]

A study of 106 cases of asphyxial deaths by hanging in New York city in the year 1967 showed two cases of accidental hanging deaths and 104 cases of suicidal

Create PDF files without this message by purchasing novaPDF printer (http://www.novapdf.com)

deaths. Commonest ligature material used was rope. Other ligature materials employed were electric cord, bedsheets, neck ties, scarf, dog leash etc. In 98% of the cases, a furrow was present in the region of the neck and in the majority of the cases, the mark was above the level of thyroid cartilage. In more than 80% of the cases it was an interrupted ligature mark , the colour of the ligature mark varied between yellowish brown to dark brown and with the increased duration of suspension and the type of ligature material used their was a hard ,leathery feel of the skin over the ligature mark. No fracture of the thyroid cartilage or hyoid was found.[5]

In the year 1973 they quoted that, in hanging deaths the ligature mark lies above the level of thyroid cartilage in 80% of cases, at the level of thyroid cartilage in 15% of cases and it lies below the thyroid cartilage in 5%. Both hard and soft ligature materials were commonly employed and atypical ligature marks are common. Although uncommon but a few cases of hyoid bone fractures and fractures of thyroid cartilage were noted.[6]

In a study conducted on fracture of hyoid bone in cases of hanging and strangulation deaths in Hyderabad in the year 1978 on 168 cases of hanging and 30 cases of strangulation deaths the results were noted as follows; In cases of hanging, the youngest was a male of 15 years and the oldest was a man of 80 years. 35.7% of cases were in the age group of 20-29 years followed by 20.8% in the age range of 40-49 years and 20.3% of cases in the age range of 30-39 years. 8.3% of the cases were in 50-59 years age group and 6.6% in 60-69 years age group. Of the 168 cases of hanging, 148 (88%) victims were male and 20 (11.9%) females. The material used for hanging were hard materials in 134 males & 13 females and soft material in 14 males &

Create PDF files without this message by purchasing novaPDF printer (http://www.novapdf.com)

7 females. The position of the ligature mark of hanging in 152 cases (90.5%) was above the thyroid cartilage and in 16 cases (9.5%) it was across the thyroid cartilage and nil below the larynx. Fracture of hyoid bone was present in 10 cases (6%) of hanging. All cases except one were male and used hard material like rope. 8 of them were aged above 40 years. The fracture occurred in right horn in 7 cases, left horn in 2 cases and was bilateral in one case. The displacement of the posterior small fragment was outward in all the cases. The hyoid bone fracture is usually associated with hemorrhages at the site of fracture.[7]

A study of 201 cases of deaths due to hanging in 1984 showed that 95%were suicidal in nature and majority of the persons were over 50years of age with a male predominance. The scene of hanging mostly was home, point of suspension being banisters, door knobs and clothes hooks on doors.150 cases were partial hanging deaths and only 51 cases were complete hanging. In 185 cases atypical ligature marks were seen and hard ligatures were used in 145 cases and soft ligatures in only 56 cases. Slipping knot was commonly employed with posterior knot mark in the majority of the subjects. Postmortem revealed no fractures of laryngeal cartilages congestive changes were prominent at base of tongue with minimal bruising.[8]

According to him in hanging deaths complete suspension of the body is noted with atypical ligature marks. The suicidee uses any material that is readily available to commit hanging and commonly the ligature mark lies above the level of thyroid cartilage. In partial hangings ligature marks overriding the thyroid cartilage and below the level of thyroid cartilage were noted. Fractures may occur but are by no means invariable; much depends upon the age of the subject. The ligature may be so firm and

Create PDF files without this message by purchasing novaPDF printer (http://www.novapdf.com)

applied so rapidly that vital reaction is absent; a false impression of a postmortem origin may be gained.[9]

In a study conducted on 160 cases of suicidal hanging deaths of which 134 cases were studied retrospectively and 26 were studied prospectively. Amongst the 26 cases studied prospectively, the ligature material employed was rope in 20 cases, electric cord in 4 cases and cloth belt in the remaining cases. The level of the ligature mark was above the thyroid cartilage in 20 cases and at the level of thyroid cartilage in 3 cases, in the remaining cases it was not recorded. In the majority of the cases, the ligature mark was yellow or brown and parchmentised, in a few cases, it was bluish, in 3 cases, neck markings had reddish or pink colour suggestive of intravital reaction.[10]

They quoted that the deepest impression is opposite the suspension point, marks are generally deeper on the front and sides of the neck, than at the back where the neck structures are firmer and less accommodating a noose. Impression left on the skin is in the region of the knot, the mark follows an upward course to form an inverted V, the apex of the V corresponding with the site of the knot. Mark is generally yellowish or yellow/brown and often dried. Often a thin line of congestion will be seen above or below the groove at some point but usually the deepest. When the suspension point is behind the ligature may encircle the neck almost horizontally, particularly when it is partial suspension. Two thirds of hanging cases studied below the age of 30 years showed fractures of the superior horn of thyroid cartilage are approximately equal to fractures of greater horn of thyroid.In general the frequency with which these fractures occur varies considerably in different series. A detailed microscopic examination of the mark may confirm the presence of effusion of red cells,

Create PDF files without this message by purchasing novaPDF printer (http://www.novapdf.com)

possibly with separation of fibrin and cellular elements, but no evidence of tissue reaction.[11]

A prospective study of 61 deaths by hanging at USA in1985 was conducted and it was found that the material used for hanging were rope or clothes line in 32 (52.4%) cases, leather belt in 8 (13.1 %) cases, soft belt or neck tie in 7 (11.47%) cases, a length of sheet or other cloth in 6 (9.8%) cases and other ligature material in 8 (13.1 %) cases. The width of the ligature that was recorded ranged from 25.4 mm or less in 46 (75.4%) cases and was greater than 25.4 mm in 7 (11.4%) cases. The site of the ligature knot was at the left side of the neck in 20 instances (32.8%), at the right side and at the back of the neck in 17 cases (27.9%) each, and at the front of the neck in 3 cases (4.9%). The ligature consisted of a single circumferential wrap in 52 (85.2%) cases, 2 wraps in 6 (9.8%) cases and 3 or more wraps in 3 (4.9%) cases. The length of the ligature material from neck to a fixed point of attachment was less than 305 mm in 5 (8.19%) cases and greater than 305 mm in 41 (67.2%) cases. In reference to the position of the body, 20 (39.3%) victims were found completely suspended and 26 (42.6%) victims were found with only their feet touching the surface. In 6 (9.83%) cases bodies were partially supported and in 4 (6.5%) cases the bodies were largely supported below the suspension point. In 5 (8.9%) cases this could not be ascertained. In 45 (73.7%) of the 61 cases the ligature impression was located superior to the thyroid cartilage prominence. Strap muscle hemorrhage was independent of the age of the victim was found in 14 cases. Fractures of the hyoid bone or thyroid cartilage were present in three strap muscle hemorrhages cases. 6 of the 14 cases with hyoid fractures and 5 of the 8 cases with thyroid fractures failed to exhibit either soft tissue or strap muscle hemorrhage. Cervical vertebral fractures were absent in all cases. Fracture of

Create PDF files without this message by purchasing novaPDF printer (http://www.novapdf.com)

the larynx or hyoid bone were present in 16 (26%) cases and was not identified in 45 cases. The hyoid bone was fractured in 14 (22.9%) cases and the thyroid cartilage was fractured in 8 cases. No fractures of the cricoid cartilages were identified.[12]

110 cases of hanging deaths at Northern Ireland was studied in 1986 of the 110 cases, 105 cases were suicidal and 5 were accidental. It was observed in the majority of cases, the act took place in the house (71.4%). The most common point of suspension was a rafter, joist or beam (43.8%). It was noted that 53.3% victims were touching the ground, and 42.9% victims were fully suspended. Ligature material commonly used was rope in 51.4% of cases, electric flex in 8.5% cases, belts in 7.6% cases, baler twine in 6.6% cases and washing line in 5.7% cases. 69.5% cases had used a slip knot, 8.6% had used a fixed knot. In 7 cases ligature mark was below thyroid cartilage. Bruising of the neck muscle was found in 2.9% cases, one of the horns of the hyoid bone was fractured in 26.7% cases, superior horn of thyroid cartilage fractured in 34.3% cases. In 16.2% of cases both hyoid and thyroid cartilage was fractured. 1 case had fracture of cervical 7th vertebrae.[13]

In a study of 56 cases of hanging deaths in 1987 he noted 50 were males (90%)and 6 were females(10%) . The location of hanging episodes were mainly home in 24 cases, jail in 15cases and they were mainly classified as inside in 51 cases and outside in 5 cases. Ropes and belts accounted for 50% of instruments used as ligature material. Sheets, electric cords, shirts, towels, linens, and other rare instruments were used in remaining cases the most unusual instruments were a clothes hanger (1case) and the traction rope on an orthopedic device used to commit suicide in a hospital (1case). Belts predominated in jail hangings. Hard ligatures were commonly employed

Create PDF files without this message by purchasing novaPDF printer (http://www.novapdf.com)

with a fixed loop.40 cases showed complete hanging and partial hanging was seen in 16 cases. Ligature mark was above the thyroid cartilage in 50 cases and in six cases it was overriding the thyroid cartilage.Parchmentisation of the ligature mark was seen in only 44 cases.No fracture of the thyrolaryngeal cartilage was detected.[14]

In a study of 80 consecutive cases of asphyxiation deaths due to hanging in Denmark in1988 revealed that the police reports, medical histories, photographs were used as modes for collecting information as to scene of occurrence, complete / incomplete hanging and duration of suspension.77cases (96.2%) were suicidal, 3 cases (3.7%) were accidental. 61 cases(76.2%) were atypical and 19(23.7%) were typical. In 30(37.5%) cases the hanging was complete and in 50(62.5%) cases, it was partial hanging. In 60 cases(76%) the ligature mark was above the thyroid cartilage and in 15 cases(19%) it was overriding the thyroid cartilage and in the remaining it was below the level of thyroid cartilage. In 70 cases(90%) soft ligature materials were employed and in 10cases(10%) hard ligatures were used. Parchmentisation of the ligature mark was observed in only 52 cases(65%).In 3cases(3.7%) fracture of hyoid bone was noted.[15]

Four unusual hanging deaths at Australia were studied in 1988. The first victim, who had undergone total laryngectomy for carcinoma larynx, hanged himself in a standing position with a cord ligature. The ligature mark was above the tracheostomy wound in a V shape with intense cyanotic congestion of the face and upper neck.The ligature mark was above the thyroid cartilage with a prominent grooving of the skin with parchmentisation.No internal fractures were detected . The second victim was a known psychotic, who with the help of a rope ligature, hung himself from a tree. The

Create PDF files without this message by purchasing novaPDF printer (http://www.novapdf.com)

ligature mark was just above the thyroid notch with fresh abrasions of the skin immediately below the ligature consistent with upward slippage of rope during suspension.The ligature mark was yellowish brown in colour,with extravasation of blood at the margin of the ligature mark. The third victim had hung herself with a electric cord by partial suspension, with feet touching ground. A circumferential parchment like brown coloured ligature was located round the neck above the thyroid notch and rose to a V at the angle of mandible on the right side with no internal injuries in neck.[16]

They stated that a broad ligature will produce only a superficial mark, if the ligature is passed twice round the neck, a double mark, one circular and the other oblique may be produced. Ligature may have one, two or more layers. Heavier the body and greater the time of suspension, more marked is the ligature impression .The mode of application of the ligature and the position of the knot, level at which the loop lies is important to distinguish between hanging and strangulation. The level of the ligature mark at or below the thyroid cartilage used as a criteria for distinguishing the above. In hanging, internal injuries are remarkably infrequent and when present suggest that some violence has occurred such as from a drop. In addition to soft tissue injuries, which are infrequent, fractures may occur in both larynx and hyoid. The frequency with which these occur varies considerably in different series. In the authors own study, fractures of the superior horn of the thyroid cartilage are approximately equal to the fractures of the greater horn of the hyoid.[17]

A 15 year retrospective study of 84 cases of suicidal hanging deaths at United Kingdom in 1992 revealed most victims selected rope for the ligature, either man made

Create PDF files without this message by purchasing novaPDF printer (http://www.novapdf.com)

or natural fibre. Other materials that were used are wire, chain, flex, belts and various soft materials. A single ligature mark above the level of thyroid cartilage was observed in 70cases(83.33%). In all but one case the mark was oblique and interrupted in that one case which was partial hanging it was a transverse mark overriding the thyroid cartilage. The ligature mark was dry and parchmentised in 72cases(84%).In 60cases(71.42%)the knot mark was on the back of neck with slipping noose. Asphyxial signs in the form of petechial haemorrhages was seen in 72cases(84%). They claim that petechial hemorrhages are the result of increased venous pressure and that their presence in partial hanging indicates venous obstruction without arterial obstruction, whereas their absence in complete hanging is due to mere constriction of the neck causing carotid obstruction and thus preventing venous congestion.. It was concluded that petechiae / congestion were not associated with ligature type, it was found that fractures were less likely to be found when a soft ligature was employed.[18]

They studied hanging deaths in infants and children in the year 1993 which were all partial hangings. The ligature mark was like a abrasion furrow or an area of pattern lividity, reflecting the imprint of the overlying ligature. Specifically they were seen in all cases in which cloth was caught on the part of a crib or infant caught in a seat belt etc. In the author's experience, the incidence of asphyxial sign like intense petechiae seems to reflect the degree of body suspension. In suicidal hangings, the ligature tightens rapidly and completely around the neck, effectively occluding both the arteries and veins. When the constriction of the neck is incomplete, petechial hemorrhages will be intense.[19]

Create PDF files without this message by purchasing novaPDF printer (http://www.novapdf.com)

A study of 61 cases of hanging deaths in Saudi Arabia in 1994 showed 48 cases of complete hanging and 13 cases of partial hanging, all victims of partial suspension used a soft ligature, most victims used running noose and in majority of the cases, there was a single ligature mark and 6 cases showed multiple ligature marks. 26 cases were suspended from the right side of the neck and 29 from the left, 4 were from the back. Asphyxial signs were more prominent in the complete suspension. Complete suspension by hard plastic clothes showed a deep narrow well defined mark above the level of thyroid cartilage, whereas cases of incomplete suspension by softer cotton cloth showed shallow broad ill defined mark, below the level of thyroid cartilage. The ligature mark was yellow to brown in colour in most cases, however soft ligatures produced faint or pale marks with no apparent abrasions. The level of the ligature mark was low in 15 cases, high in 40 cases. The depth was shallow in 15 cases and deep in 40 cases. The width was more than 2 cms in 21 cases and less than 2 cms in 34 cases.[20]

A prospective study of 80 cases of suicidal hanging deaths at Norway in 1996 showed that there were 41 cases (51.2%)of complete suspensions while 39 cases (48.7%) were incomplete. There were 28 cases (35%)of typical and 52 cases (65%) of atypical hangings. In 65 cases (82%) soft ligatures were employed and in the remaining hard ligatures were employed. The ligature mark was single in 68cases (85%) and double in 4cases (5%). The ligature mark as placed above the level of thyroid cartilage in 44cases (55%) and in 34 cases (42.5%) it was overriding the thyroid cartilage and in 2cases(2.8%) it was below the thyroid cartilage. The ligature mark was reddish brown in colour in 25 cases (31.25%) and parchmentisation was seen in 58cases(72.5%). 8 cases (10%) showed fracture of greater cornu of the hyoid bone and in 7cases(9%)their was a fracture of the thyroid cartilage. The highest frequency of

Create PDF files without this message by purchasing novaPDF printer (http://www.novapdf.com)

fractures was found in atypical complete hangings. Radiography has been recommended prior to dissection. The proportion of fractures seemed to increase with age and possibly also with increase in suspension time.[21]

In the year 1996 they evaluated a total of 109 cases of suicidal or accidental hanging deaths in Germany and the number of hyoid bone or thyroid cartilage fractures or both was investigated in relation to the highest point of the ligature mark and to the age of the deceased. They have divided the hanging victims into 8 groups, depending upon the topographical location of the highest point of the ligature mark. They are Middle of chin, Right anterior, Right ear, Right posterior, Middle of occiput, Left posterior, Left ear and Left anterior. 50% of the cases (four of eight) with a location of the highest point of the ligature mark in front of the ears showed positive results, whereas 68% (69 of 101) of the individuals with a highest point at or behind the ears gave positive findings. Even though a higher incidence of positive results and in particular of multiple fractures could be established in cases with a highest point of the ligature mark at or behind the ears, no clear correlation between frequency and number of throat-skeleton fractures was detectable in our series.[22]

They studied 61 cases of hanging deaths in1998, which comprised 43% of all violent asphyxial deaths in Imphal. Ligature mark was oblique in all the 61cases(100%). Ligature turn was single in 96.7% and was double in 3.3% of the cases. In 50 cases (81.96%) the mark was above the level of thyroid cartilage and in 11cases(18.5%) it was overriding the thyroid cartilage. Prominent ligature mark was observed in 47 cases (77.33%). The colour of the ligature mark was reddish in36% of the cases, followed by brown colour in 31.2%. The colour was pale in 19.7%of the

Create PDF files without this message by purchasing novaPDF printer (http://www.novapdf.com)

cases. Ligature mark showed parchmentization in 13% of cases. Tissues underneath the ligature marks were pale in 47.5%, glistening white in 18%, contused in 27.9%. There was extravasation of blood in 6.6%. None of the hanging cases had a fractured thyroid cartilage. The hyoid bone was fractured in 4.9% of the cases.[23]

In a study of 127 cases of hanging deaths at New Delhi in1998 showed that ligature mark was single in 124 cases and was multiple in 3 cases. The knot was single in 126 cases and multiple in 1 case. Its position was high in 124 cases and middle in 3 cases. The direction was oblique in all the 127 cases. In 126 cases, the ligature mark was incomplete. In 121 cases, the ligature mark was pale and parchmentised, soft and red in 5 cases and ecchymosed in 1 case. Slipping of ligature mark was seen in 24cases. Slipping noose was applied in 98cases. Asphyxial signs in the form of cyanosis, petechial haemorrhages seen in 120cases. Fracture of hyoid bone was seen in 12cases. [24]

In the year 1998 they studied 12 cases of paediatric hanging deaths and concluded that asphyxial signs were more prominent in incomplete hanging. 6 cases of complete hanging showed hard ligatures around the neck with deep grooving on the front and sides of neck. Complete suspension leading to rapid death in the children is responsible for the lack of petechial haemorrhages that was seen in the autopsies. In none of the cases fracture of the hyoid bone or thyroid was detected. They concluded that this contrasts with the findings in adult hangings, where the reported incidence of such fractures is as high as 67%.[25]

Create PDF files without this message by purchasing novaPDF printer (http://www.novapdf.com)

A study of 50 cases of deaths due to hanging in Orissa in 1998 revealed that, 28 were males and 22 were females. Typical and complete hanging was seen in 14cases,atypical and incomplete hanging as seen in 36cases. Rope was used in 26 cases, linen in 16 cases, electric wire in 8 cases as the ligature materials. 38 victims showed intense asphyxial signs with 13 cases showing fracture of the hyoid bone or thyroid cartilage. It seems that typical hanging is especially linked to the fractures and the congestion of the face corresponds to incomplete hanging. Localization of the postmortem staining depends on the length of time body is suspended. The study concluded that the frequency of fracture increases with the increase of suspension time.[26]

A retrospective study analyzing 307 accidental and suicidal hangings for the presence or absence of neck organ fractures in U.S.A. in 1999 revealed 275 were males and 42 were females. Sixteen of the ligatures were 0.93cm in width or less. The remainder were wider i.e., 3 cm in belt, wide rope etc. In several of the cases, the ligature consisted of a strip of cloth or piece of clothing. The width of this type of ligature is difficult to define because of its tendency to compress in some regions of the neck while remaining wide in others. The width of the ligature with fractures present was commonly very narrow(<_0.93cm) Therefore, it appears that ligature width also is not of predictive value in whether or not hanging will result in a neck organ fracture. Another variable considered was whether or not the decedent was fully or partially suspended. In this review, full suspension does not appear to be important in producing fractures. This is highlighted by the finding that at least 25 of the 29 cases in which neck organ fractures were identified were definitely not or most likely not fully

Create PDF files without this message by purchasing novaPDF printer (http://www.novapdf.com)

suspended at any point in time. It was concluded that the ligature type does not seem to be of predictive value in causing fractures..[27]

He quoted that when the point of suspension is over the centre of the occiput, it is called typical hanging & point of suspension anywhere around the neck is atypical hanging. Usage of a soft ligature and if the body be cut down from the ligature immediately after death, there may be no mark. Again the intervention of a thick and long beard or clothes may lead to formation of a slight mark. Mark may be found on or below the thyroid cartilage in case of partial suspension. It may be circular if the ligature is first placed at the nape of the neck and then its two ends are brought horizontally forward and crossed, and carried upward to the point of suspension from behind the angle of the lower jaw on each side. The mark will be both circular and oblique if ligature is passed around the neck more than once varies according to the nature of material used as a ligature and period of suspension after death. Presence of abrasions with hemorrhage around ligature are strongly suggestive of antemortem hanging. The mark is well defined narrow and deep if a firm string is used. Mark is a groove or furrow and the base is pale, hard, leathery and parchment like and the margins red and congested and deepest near the knot. The mark is superficial and broad, if a cloth or a soft rope is used. Wide band of cloth when used as a ligature on bare skin may cause a narrow ligature mark due to tension lines in the stretched cloth. Gordon et al, suggested presence of tissue reaction, indicate antemortem hanging. But the absence of tissue reaction does not exclude antemortem hanging. Out of the 33 cases of hanging, fracture of hyoid bone were seen in 3 cases and the individuals were aged more than 40 years and a hard ligature was used.[28]

Create PDF files without this message by purchasing novaPDF printer (http://www.novapdf.com)

They studied 40 cases of suicidal hanging deaths in the year 2000 and concluded that higher rates of fracture was present with complete suspension. Hard ligature materials were commonly employed by the deceased and atypical ligature marks were observed in 30 cases (90%) .The maximum width produced by the ligature material was 4cms.35 cases(95%)showed ligature mark above the level of thyroid cartilage and 4cases(4%)showed ligature mark overriding the thyroid cartilage and in only one case the mark was below the level of thyroid cartilage. Hyoid bone fracture was noted in 4 cases (4%) and all the 4cases showed complete suspension with hard ligatures.[29]

According to him ligature mark is usually above hyoid bone, oblique and passing backwards and upwards symmetrically on either side to the point of suspension. Mark is not seen at the point of knot or where there is intervening hair or clothing. At times there may be more than one ligature mark when the material has been wound around the neck more than once. In such cases, the skin between the ligature marks will appear bruised due to pinching.[30]

They studied 146 cases of hanging deaths in 2001, out of which 36 cases were partial hanging. Rope was the ligature material in 62%, dhothi in 16%, and other soft material 23% of cases. 39% of the cases showed less than 2.2cms width of the ligature mark and 61% showed more than 2.5 cms. 65% cases showed single ligature mark, 35% double ligature. 77% of cases showed ligature mark above the level of thyroid and 23% showed mark overriding the thyroid. Fracture of hyoid bone was detected in 14 percent of cases. 15 percent of cases showed fracture of thyroid

Create PDF files without this message by purchasing novaPDF printer (http://www.novapdf.com)

cartilage and 16% of cases showed interstitial hemorrhages on the thyroid gland. Fractures were more common in complete hanging than in partial hanging.[31]

In a study conducted at Bangalore in 2001 comprising 246 cases of suicidal hanging deaths. 138(56.08%) victims were male and 108(43.9%) were female. The age range comprised from 14 to 68 years. Majority (86.1%) of the victims were aged below 40 years and only 13.8% of the victims were aged above 40 years. Most hanging deaths occurred indoors (99.5%). Soft materials were used in 63.4% and hard materials were used in 32.9%. 213 cases (86.58%) were complete hanging and 33 cases (13.41%) were partial hanging. 26.42% of the cases were typical hanging and 68.6% were atypical hanging deaths. The position of the knot was occipital in 26.4%, right occipital in 15.4%, left occipital in 17.1%, near the chin in 2.8%, right ear in 16.3%, left ear in 17.1% and not known in 4.9% of cases. Deaths were noticed by the relatives within 8 hours of suspension in 64.22% of the cases and within 8-16 hours in 28.86% of cases. Ligature mark was present in 98.78% of the cases. Ligature mark was present above the level of thyroid cartilage in 75.72% of cases, on the thyroid cartilage in 18.93% and below thyroid cartilage in 5.34% of cases. Skin underneath ligature was hard and parchmentised in all cases, except decomposed cases. The size of the ligature mark varied from 14-42 cms in length and 1cm to 6 cms in breadth. The soft tissue under the ligature mark was pale and glistening in all cases, except in decomposed cases. There was neither extravasation of blood nor muscle tears/ruptures/intimal tear of carotid vessels. Hyoid bone and thyroid cartilage were intact/not fractured in all cases.[32]

Create PDF files without this message by purchasing novaPDF printer (http://www.novapdf.com)

They undertook a study at Jamnagar in 2002 comprising of 23 cases of hanging deaths. 15 victims were male and 8 were female. The age range was from 11years to 80 years and the commonest group was between 21-30 years. Most commonly used ligature material was cotton rope followed by saree and nylon rope. Fixed noose was found in 52.2% cases, sliding noose in 39.1% and without noose in 8.7% of cases. 39.2% of the cases were typical hanging and 60.8% were atypical hanging. 60.8% of cases were completely suspended, while 39.2% of the cases were partially suspended. The highest level of ligature was at the back of the neck in most of the cases. In 69.6% cases duration of suspension was less than 6 hours, in 17.4% it was between 6-12 hours and in 8.7% it was more than 12 hours. Duration of suspension was not known in 4.3% of the cases. In 39.1% of cases breadth of ligature mark was less than 1 cm, in 30.4% cases it was 1-2 cm and in 4.3% of cases it was 4-5 cms. In 4 cases(17.4%) injury to the hyoid bone was observed and no other osteo cartilagenous structure was found to be involved. In hanging ligature mark is commonly located in upper part resulting in compression on the hyoid bone to greater extent as compared to rest of osteo cartilagenous structures. The incidence of injury to hyoid bone is increasing with increase in age upto 50 years and with typical and complete type of hanging. The incidence of injury to hyoid bone was higher in cases with highest level of ligature mark at the back of middle of neck. The incidence of fracture of hyoid bone is higher in cases not showing congestion of face. The incidence of fracture increases with increase in duration of suspension and is higher with narrow ligature mark.[33]

He quoted that if the ligature material is tough and narrow, the mark is expected to be deep and prominent, but if the material is soft and broad, mark is less

Create PDF files without this message by purchasing novaPDF printer (http://www.novapdf.com)

prominent and less deep. It may be at the level of the thyroid cartilage in about 15% and below the cartilage in about 5% of hangings. In complete hanging, the ligature mark is more prominent as compared to partial hanging. In most hangings, fixed loop is applied when the mark appears in the form of a groove or furrow, being deepest opposite to the knot. Mark is generally yellowish or yellowish brown shortly after death and gets dried and assumes parchment like consistency. Fracture is more frequent in persons over 40 years. Fracture of the superior horn of the thyroid cartilage are approximately equal to fractures of the greater horn of the thyroid bone and related to state of ossification of these structures.[34]

A study of 75 case of violent asphyxial deaths between 1999 and 2002 at the All India Institute of Medical Sciences, New Delhi showed that out of 60cases of hanging 36 were males and 24 were females. Out of the 60cases 26 were in the age group of 21to 30. Rope (plastic & fibre) was used as ligature in 25cases of hanging, dupatta was used in 16cases of hanging, saree in 10 cases, bed sheet in 3 cases, lungie in 2 cases, plastic water pipe in 2 cases, ligature material not known in others. Out of the 60 cases in 58 cases (96.92%) the ligature mark was placed above the thyroid cartilage and 2 cases (3.08%) showed mark at the level of thyroid cartilage. In all the 60 cases of hanging, the ligature mark was placed obliquely. In all the 60 cases of hanging the ligature mark was not completely encircling the neck circumference. Ligature mark was single in 59 cases of hanging and multiple in only one case. The ligature mark was reddish brown in colour in 25cases of hanging (41.66%), pale in 13 cases (21.66%) and parchmentisation was seen in 22 cases (36.66%). The colour of ligature mark depends largely on the duration of suspension of the body and the nature of the ligature material used.[35]

Create PDF files without this message by purchasing novaPDF printer (http://www.novapdf.com)

They quoted in 2002 that the antemortem nature of hanging is ascertained by salivary dribbling from the mouth, Lefacie sympathique, biochemical markers and microscopic study of ligature mark revealing vital reaction. When a tough ligature material like coir or nylon rope is used, produces “rope burn” which also signifies antemortem hanging. They are caused by the friction of rope against skin& such friction generates heat, which produces blisters (second degree burns) by expressing tissue fluid into upper layers of skin, measuring 1-3 mm in diameter as also described by Werner V Spitz. A careful and meticulous examination of neck is necessary in all cases of hanging, or else vital evidence could be lost. However possibility of blisters being produced after death due to putrefaction should be in mind, but analysis of blister contents will unreveal the mystery. Therefore rope burns (blisters) around the ligature mark helps to ascertain antemortem nature of hanging which is one of the periligature injuries and thus of immense value in the course of investigation.[36]

They quoted in 2003 that ligature mark is a vital evidence in asphyxial deaths. The course and direction of ligature mark helps in determining the type of asphyxial death as hanging or strangulation. The pattern and direction of the nail marks over the neck will help us to interpret the nature of their causation, throttling or suicidal hanging. A victim may often try to extricate or remove the ligature by using his or her hand. During the process of removal of the ligature the nails of the victim produces periligature injuries, which are on examination revealed to be scratch abrasions. In victims of ligature strangulation such scratches may be found near the ligature mark and are usually vertical, but may be irregular or crescentic. The victims of suicidal

Create PDF files without this message by purchasing novaPDF printer (http://www.novapdf.com)

hanging may attempt to pull away the ligature as a reflex action to preserve life, thus inflicting nail marks on the neck. In attempted resuscitation, nail marks can also be produced by the rescuer while trying to remove the ligature. In case of hanging apart from giving an opinion on the cause of death, the forensic pathologist has to comment on the nature of hanging as antemortem or postmortem.A saliva dribble mark is the classical feature of antemortem hanging, but may not be present in all cases. Rope burns which are produced when tough ligature material like coir or nylon rope is used because of friction between skin and ligature material helps us to ascertain antemortem nature of hanging. It is vital to correlate them with other findings before opining the manner of death.[37]

They did a retrospective study of suicidal hangings on 175 cases in Belgrade in 2003 and the study population was divided in 4 groups according to the position of the ligature knot (24 were anterior, 21 were right, 22 were left, and 108 were posterior hanging). 133 male victims and 42 female victims all aged between 10 and 87 years were studied. The authors analyzed all visible injuries of soft tissues and bones and cartilage of the neck, and in 150 cases (85.7%), they established that there was at least one injury of these structures. The most frequent injury was to sternocleidomastoid muscles. Fracture of throat skeleton was detected in 119 cases (68%). A 2-fold fracture of the greater horn of hyoid bone occurred in 7 cases (3 posterior and 3 anterior hangings and 1 right hanging). A single fracture of the left greater horn of the hyoid bone was found in 14 cases, while a fracture of the right greater horn of the hyoid bone occurred in 12 cases. Horn thyroid cartilage fractures accompanied by hyoid bone fractures were identified in 5 cases (1 right hanging and 4 posterior hangings). A possible mechanism of these fractures is assumed to be the pressure that

Create PDF files without this message by purchasing novaPDF printer (http://www.novapdf.com)

the horns of these structures exert on to the spine because of a greater traction in the posterior hanging type. There was no clear correlation between frequency of neck injuries and the ligature knot location. The hyoid bone fracture could also be caused by other factors like point of the ligature, and width of the ligature. The conclusion could be that the frequency of the left and right horn thyroid cartilage fractures varies in relation to the location of the ligature knot. Fracture of either the left or right superior horn of the thyroid cartilage is the most frequent in the right hanging type.[38]

According to him the hanging mark almost never completely encircles the neck unless a slip knot was used, which may cause the noose to tighten and squeeze the skin through the full circumference of the neck. Successful hanging can occur from low suspension points. The mark is usually situated higher on the neck than in strangulation, usually being directly under the chin anteriorly, passing around beneath the jaw once and rising up at the sides or back of the neck to usual gap under the knot. In the neck tissues, there may be no findings if a soft ligature has been used. However, the literature suggests that an average figure for the incidence of soft tissue hemorrhages would be about 20 – 30 % of cases and for laryngeal fractures approximately, 30 – 45 % of the cases. Fractures of both hyoid and thyroid may be seen.[39]

He quotes the ligature mark leaves distinct furrow of its own width and pattern on the skin surface. In general, the thinner and tougher the material used, more pronounced is the ligature mark. Similarly, the softer and broader the material, less distinct is the ligature mark. Skin in the region of the ligature mark is dry and hard. Pattern of the ligature used often gets imprinted on the skin as pressure abrasion.

Create PDF files without this message by purchasing novaPDF printer (http://www.novapdf.com)

Grooving of the ligature mark is due to congestion and associated oedema. These are generally more marked near the upper border of the mark. The ligature groove will be deepest on the opposite side of the knot when the noose is tied with fixed knot. Microscopically, the ligature mark displays the usual characteristics of abrasion showing desquamation and flattening of cells of the epidermis. If death has occurred quickly, vital reaction may be quite difficult to demonstrate. Hyoid bone fracture is seen occasionally in individuals more than 40 years of age and in whom greater cornua have fused with the body.[40]

According to him ligature mark may be single or multiple, formed into a fixed or sliding noose. The knot may be from a simple half hitch to the barrel like "Hangman's Knot". Padding of Ligature suggests sexual misadventure rather than suicide. Longer the noose, the more elongated and well defined is the inverted V shape of the neck often incomplete at the apex as the head tilts away under its own weight. The mark may be transverse and fully encircling if the ligature joins the neck at a right angle as it may do in partial suspension. Internal injury to the neck in suicidal hanging is usually confined to fracture of glosso laryngeal skeleton, the hyoid or commonly one or both superior thyroid cornua.[41]

In a study of 120 cases of hanging deaths at Bangalore in 2005, 28 cases were partial hanging and 92 cases were complete hanging. Ligature material used was soft in 101 cases, where as hard ligature material was used in 19 cases. Slipping type of noose was used in 105 cases and fixed noose was used in 15 cases. Height of suspension was more than 5 feet in 17 cases and it was less than or equal to 5 feet in 103 cases. The ligature mark was single in 117 cases and double in 3 cases. The mark was situated

Create PDF files without this message by purchasing novaPDF printer (http://www.novapdf.com)

above the level of thyroid cartilage in 95 cases, overriding thyroid cartilage in 20 cases and below thyroid cartilage in 5 cases. The width of the ligature mark was about 1.5 cms or less in 32 cases, 2-2.5 cms in 61 cases, and above 3 cms in 27 cases. The highest point of ligature mark on the neck was on the right occipital region in 34 cases, left occipital region in 32 cases, occipital region in 31 cases, right or left ear in 20 cases and right front of neck in 3 cases. The fracture of the hyoid bone was found to be less common than thyroid cartilage fracture. Left greater horn fracture of hyoid bone was more common in hanging. No clear association between the side of fracture and the site of knot is found in hanging. Compared with single ligature mark, double ligature mark on the neck was found with higher frequency of fractures. No fractures of hyoid bone were present, when the ligature mark was below the level of thyroid cartilage and also when the highest level of ligature mark of hanging was in front of ears. The fracture of hyoid bone was found to be not influenced by the completeness of suspension, typical or atypical ligature mark when the knot was behind ears, width of the mark and whether the level of the mark was above or overriding the thyroid cartilage. The hyoid bone fracture is very unlikely in a hanging victim from a height of 5 feet or less, using a soft ligature material. When the ligature mark is below the level of thyroid cartilage, fractures of hyoid bone are very unlikely. When the highest level of ligature mark of hanging is in front of ears, the hyoid bone will be reasonably intact.[42]

Create PDF files without this message by purchasing novaPDF printer (http://www.novapdf.com)

MATERIALS AND METHODS

The present study "Study of ligature mark in cases of Hanging" has been carried out in the Department of Forensic Medicine, M.S.Ramaiah Medical College and Hospital, Bangalore during the period of 2004 to 2005. Of all the cases brought to the department for medicolegal autopsy, cases in which death had resulted from hanging were identified. A sum total of 80 cases were selected for this prospective study. Permission of the ethical committee on the use of human material for research purpose was obtained.

Detailed information regarding the deceased and the circumstances of death was collected from the police and relatives. In some of the instances, this information was supplemented by either, visit to scene of occurrence or from the photographs of scene of occurrence.

SAMPLE SIZE DETERMINATION

Sample size is estimated based on the assumption that this method can approximately detect ligature marks in 90% of the cases. The sample size is estimated based on 5% significance level and 8% error.

p = 90%, q = 10% and E = 7.2 for 8% error.

$$\text{The sample size, } n = \frac{Z\alpha^2 \times pq}{E^2} = \frac{4 \times 90 \times 10}{(7.2)^2}$$

n = 73. Hence the number of cases to be studied: 80.

Create PDF files without this message by purchasing novaPDF printer (http://www.novapdf.com)

INCLUSION CRITERIA

All the cases brought with a history of hanging.

EXCLUSION CRITERIA

Decomposed bodies where the ligature mark is masked.

The hanging victims were classified on various characteristics as follows:

A. Type of suspension: 1.Complete.

2.Partial.

B. Type of ligature mark produced: 1.Typical.

2.Atypical.

C. Duration of suspension:

1. Duration of suspension less than 1 hour.
2. Duration of suspension between 1hour to 5hours.
3. Duration of suspension beyond 5 hours.

The duration of suspension was calculated by the history (time duration when the victim was last seen alive) and the autopsy findings.

Observations made during the autopsy included external examination and internal examination of the deceased. The ligature material was studied, whenever the ligature material was in situ study of the noose as slipping or fixed, number of turns and site of the knot in relation to neck was noted.

The ligature materials were classified into two groups: Hard ligature materials and soft ligature materials. Ropes, metallic chains, etc were considered as hard. While saree, dupatta, lungi and towel etc were considered to be soft ligature materials.

External examination of the neck was conducted to study the ligature mark/s and other periligature injuries. Number of ligature mark/s, topographical location of the highest level of ligature mark, width of the mark, orientation of the mark, level of

Create PDF files without this message by purchasing novaPDF printer (http://www.novapdf.com)

ligature mark in relation to the thyroid cartilage and other features were noted. Skin over the ligature mark was sent to department of Pathology at M.S.Ramaiah Medical College and Hospital for histopathological examination to note the nature of ligature mark as antemortem or postmortem.

Classification of ligature marks based on the topographical location of the highest level of the ligature mark is as below:

Level I =right front of neck.

I,II =below right ear.

II = right back of neck.

II,III =center of Back (occipital, typical ligature mark)

III = left back of neck.

III,IV = below left ear.

IV =left front of neck.

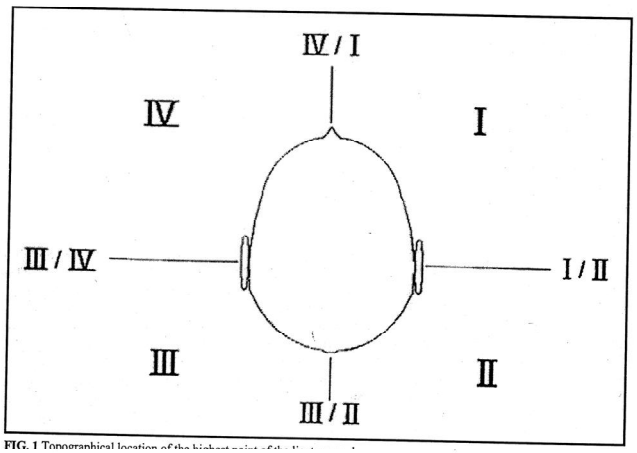

FIG. 1 Topographical location of the highest point of [illegible]

Create PDF files without this message by purchasing novaPDF printer (http://www.novapdf.com)



Plate No. 1 : Photograph shows a case of "complete hanging" with a long drop.



Plate No. 2 : Photograph shows a case of "partial hanging" (the deceased is in a kneeling position) .Note: Plastic Binder used as ligature material

Create PDF files without this message by purchasing novaPDF printer (http://www.novapdf.com)



Plate No. 3 : Photograph shows ligature mark only on the right side of the neck "Atypical ligature mark".



Plate No. 4 : Photographs showing the ligature mark encircling the neck – narrow, grooved "Typical ligature mark".

Create PDF files without this message by purchasing novaPDF printer (http://www.novapdf.com)



Plate No. 5 : Photograph showing a broad "Prominent and parchmentised mark" situated "Above the thyroid cartilage".



Plate No. 6 : Photograph showing the ligature mark which is "Over riding" the thyroid cartilage

Create PDF files without this message by purchasing novaPDF printer (http://www.novapdf.com)



Plate No. 7 : Photograph showing a "Faint ligature mark" situated "Below the level of thyroid cartilage".

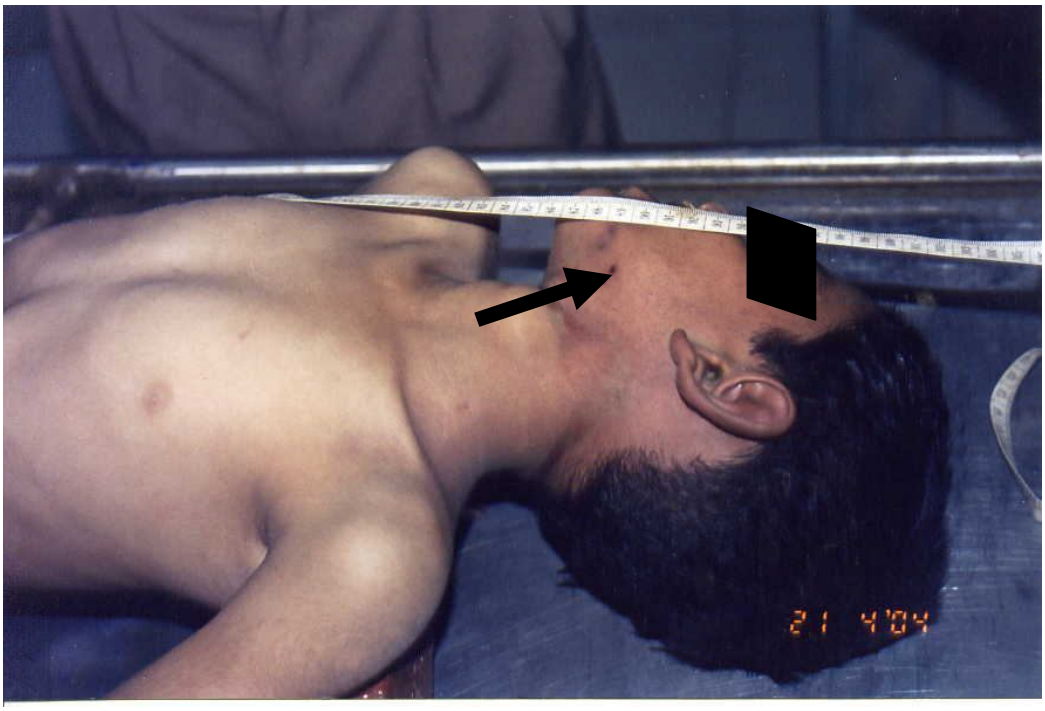

Plate No. 8 : Photograph showing "Periligature injury" – abrasion over the left angle of mandible.

Create PDF files without this message by purchasing novaPDF printer (http://www.novapdf.com)



Plate No. 9 : Photograph showing "Multiple ligature marks" with ligature material in situ and material being cut away from the knot. Note: Pattern of the ligature material reproduced over the skin.

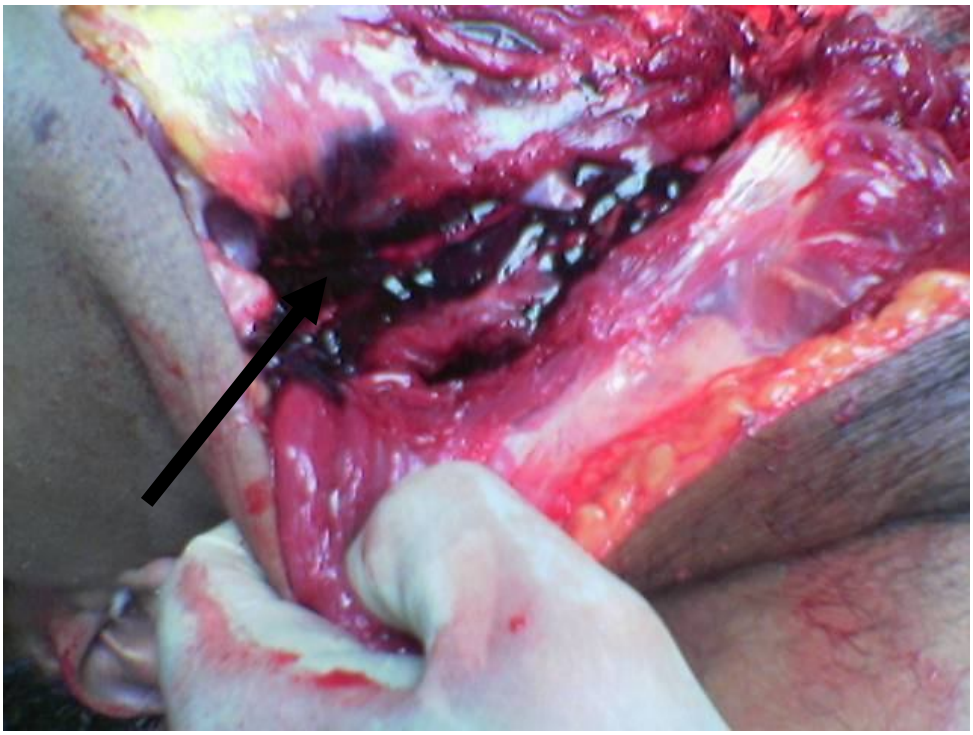

Plate No. 10 : Photograph showing "Extravasation" into the tissues over the right side of the neck in the case of long drop.

Create PDF files without this message by purchasing novaPDF printer (http://www.novapdf.com)

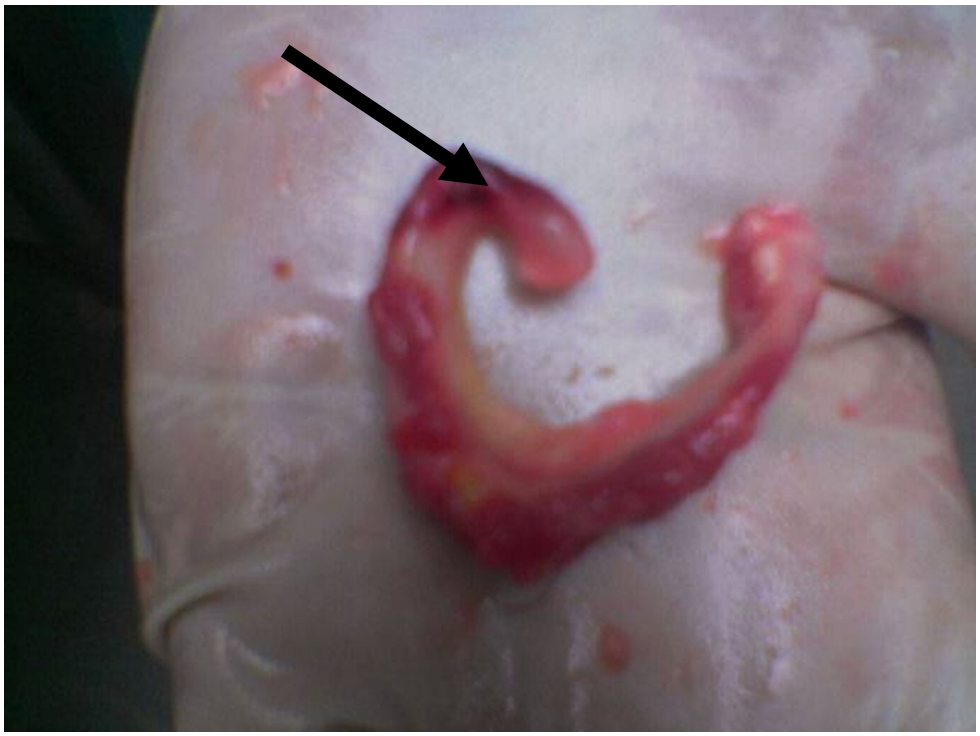

Plate No. 11: Photograph showing "Fracture of right horn of Hyoid bone" in an elderly individual.

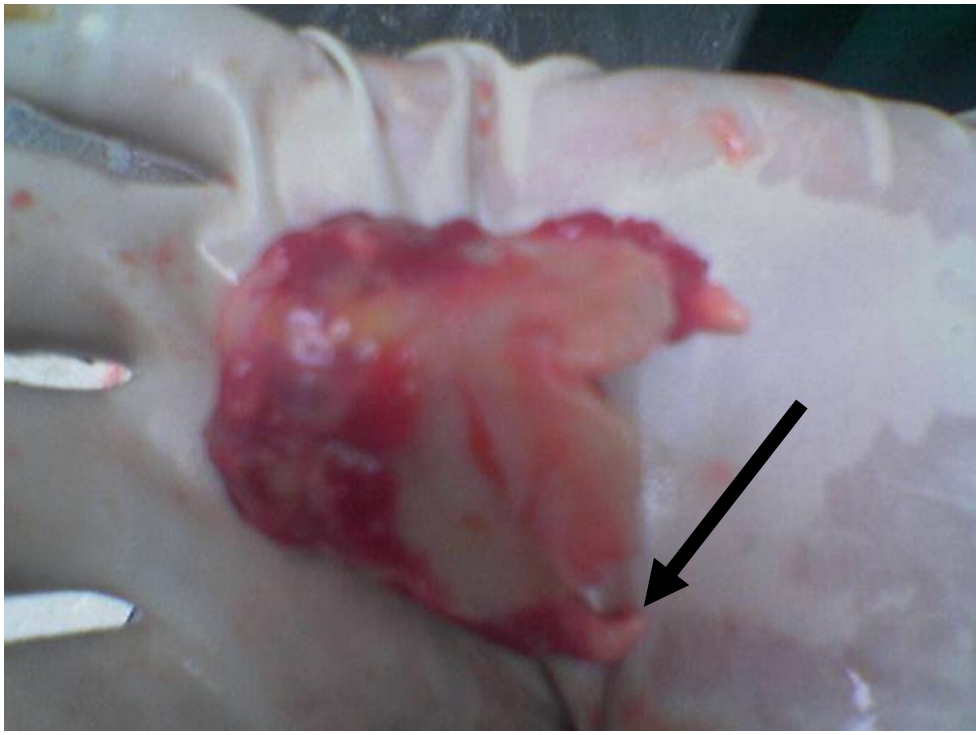

Plate No. 12 : Photograph showing "Fracture of left cornua of the thyroid cartilage" in a case with multiple rows of ligature applied around the neck

Create PDF files without this message by purchasing novaPDF printer (http://www.novapdf.com)

Photograph showing various types of ligature materials



Photo 13 : Hard : coir rope



Photo 14 : Plastic binder



Photo 15 : Soft : Cloth



Photo 16 : Nylon rope

Create PDF files without this message by purchasing novaPDF printer (http://www.novapdf.com)

RESULTS AND DISCUSSION

Age and Sex distribution in the study population.

TABLE 1 : Age

Sl. No	Age (years)	No. of cases	%
1	10-19	20	25
2	20-29	30	38
3	30-39	18	23
4	40-49	7	9
5	50-59	3	4
6	> 60	2	1
	Total	80	100

TABLE 2 : Sex

Sl. No	Sex	No. of cases	%
1	Male	47	59
2	Female	33	41
	Total	80	100

It is observed from the above table that maximum no of hangings in the study population are seen in the age group 20-29 years (38%) followed by 10-19 years (25%) and 30-39 years (23%). In the sex distribution pattern males accounted for 47 cases (59%) as compared to 33 cases (41%) in females.

The influencing factors for the above distribution being unemployment, love disappointment, marital disharmony, financial problems, dowry harassment etc.

Similar findings were observed in the studies conducted by B.K.Sen Gupta[5], Gary. P. Paparo and Siegel.H,[11] Andrew Davisonand Marshall T.K.[14],Ryk James and Paul Sillocks[19] ,A. Momonchand, Th.Meera Devi and L.Fimate[24] G.A. Sunil Kumar Sharma,O.P.Murthy,T.D.Dogra.[36]

It is in contrast to the findings observed by James L. Luke,[4] David A.L.L Bowen.[7] For these studies were done in developed countries, where in there is ample employment opportunities, westernized culture and good governmental support programmes.

Create PDF files without this message by purchasing novaPDF printer (http://www.novapdf.com)

Fig 1 : Age Distribution in the study population

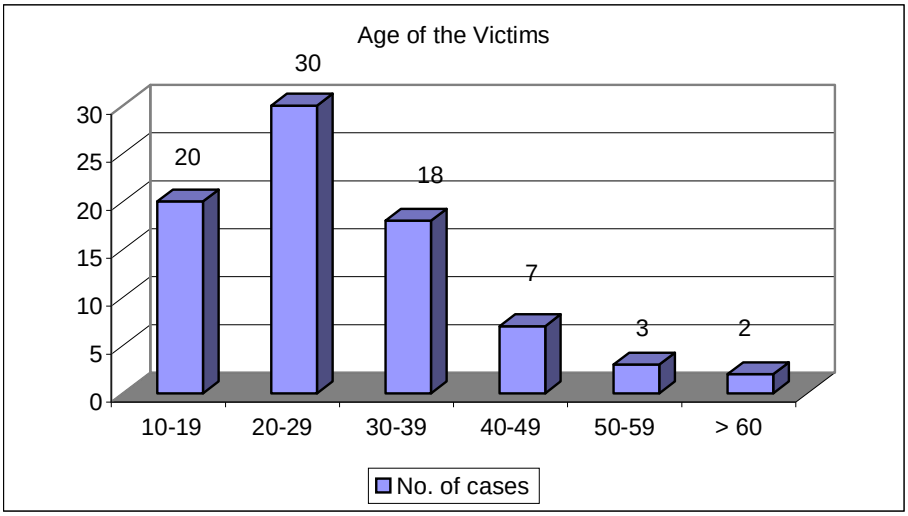

Fig 2 : Sex Distribution in the study population

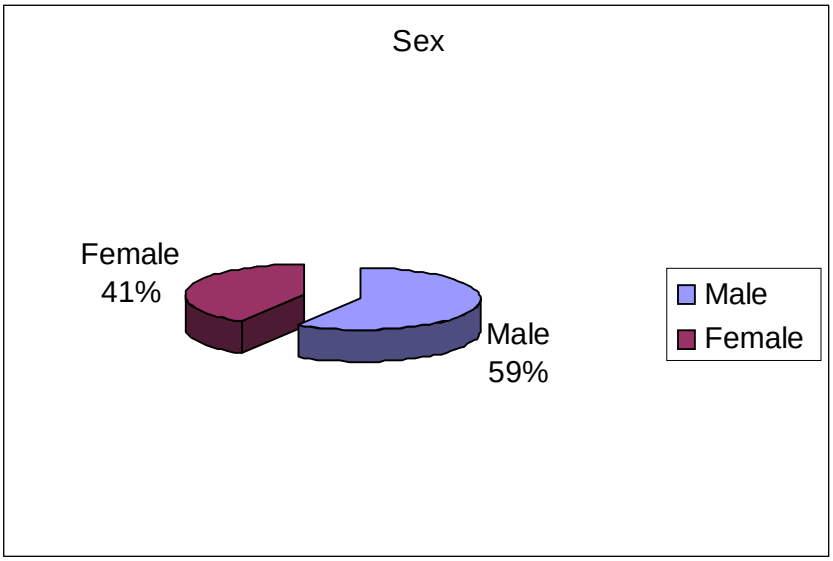

Create PDF files without this message by purchasing novaPDF printer (http://www.novapdf.com)

Distribution in the study population according to the type of hanging (suspension and ligature mark)

TABLE 3 : Degree of Suspension

Sl. No	Degree of Suspension	No. of cases	%
1	Partial	17	21
2	Complete	63	79
	Total	80	100

TABLE 4 : Ligature Mark

Sl. No	Ligature mark	No. of cases	%
1	Typical	11	14
2	Atypical	69	86
	Total	80	100

In the present study it is observed that complete suspension were noted in 63 cases (79%) as compared to 17 cases (21%) of partial suspension.

Atypical ligature mark were noticed in 69 cases (86%) as compared to typical ligature mark in 11 cases (14%)

The above observations were similar to the findings observed by Jorn Simonson,[16] ElfawalM.A, O.A. Awad,[21] Feigin Gerald,[28] Andrew Davison and Marshall T.K.[14]

The influencing factors being the majority of the study population were adult individuals who had committed suicides and hence more number of complete hanging. The position of the knot or any intervening object like clothings, bony projections (angle of the jaw), long plaits in Indian women and also the beard accounted for the majority of the mark being atypical.

It is in contrast to the findings observed by Gary P. Paparo,[11] I. Morild,[22] Jonathan P. Wyatt,Wyatt P.W.,Squires T.J.,Busuttil A [26].BalabantarayJ.K.[27] The reasons being that their study population was restricted to victims of lower age group, who had been either victims of accidental hanging or homicidial hanging.

Create PDF files without this message by purchasing novaPDF printer (http://www.novapdf.com)

Fig 3 : Distribution in the study population according to the type of hanging

Suspension

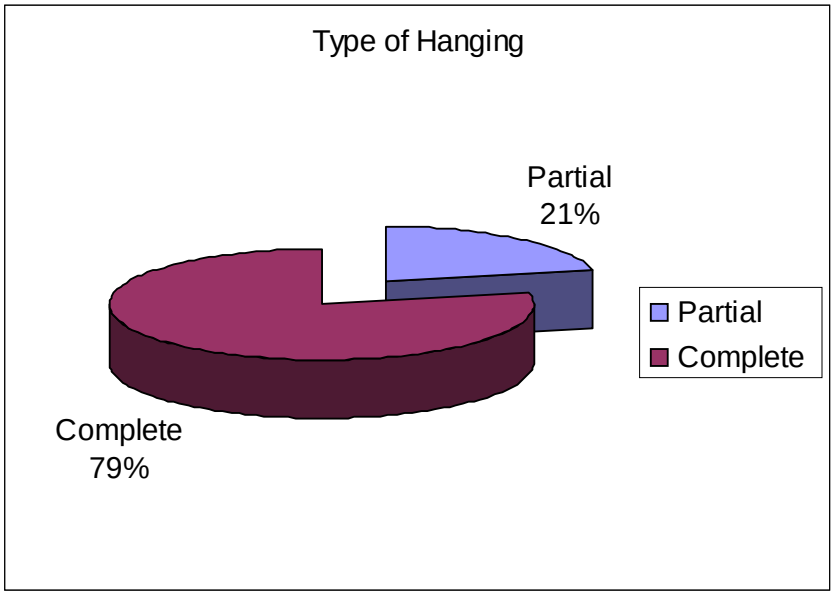

Fig 4 : Distribution in the study population according to the type of hanging

Ligature mark

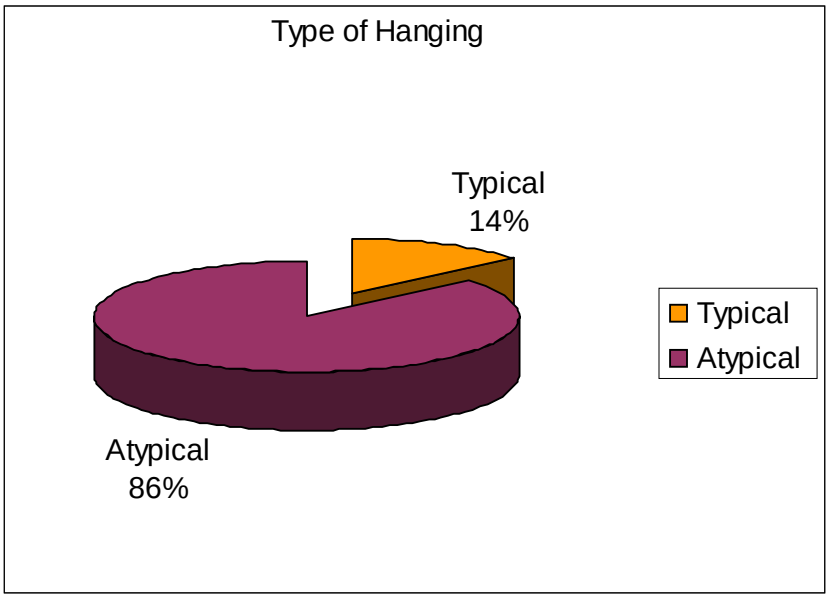

Create PDF files without this message by purchasing novaPDF printer (http://www.novapdf.com)

Distribution among the study population with respect to multiplicity of Ligature mark

TABLE 5 : Number of Ligature marks

Sl. No	Number of Ligature marks	Number of victims	%
1	One	76	95
2	Two	2	3
3	Three or more	1	1
4	Nil	1	1
	Total	80	100

In the present study it is observed that single ligature mark is seen in 77 cases (97%) as compared to double ligature mark in 2 cases (2%) and more than two ligature marks in 1 case (1%).

Similar findings were observed in the studies conducted by A.Momonchand, Th.Meera Devi,L.Fimate[24] ,Sunil Kumar Sharma, O.P.Murthy, T.D.Dogra[36] .M.P. Sarangi.[25] The reason for single ligature mark being the choice of ligature material in the majority of cases, which were strong, long and broad in nature, so as to fulfill the need. The reason for double ligature mark being the usage of rope with double noose one passing over the chin and the other one passing over the middle of the neck with a left posterior fixed knot in one case and in the other one due to slipping of the ligature and multiple ligature mark observed due to multiple rounds of the material passed round the neck. The reason for absent / faint ligature mark being a soft material that was used (Saree) and the duration of suspension was very less (30 Minutes).

Create PDF files without this message by purchasing novaPDF printer (http://www.novapdf.com)

Fig 5 : Distribution in the study population with respect to multiplicity of ligature mark.

Number of Ligature marks

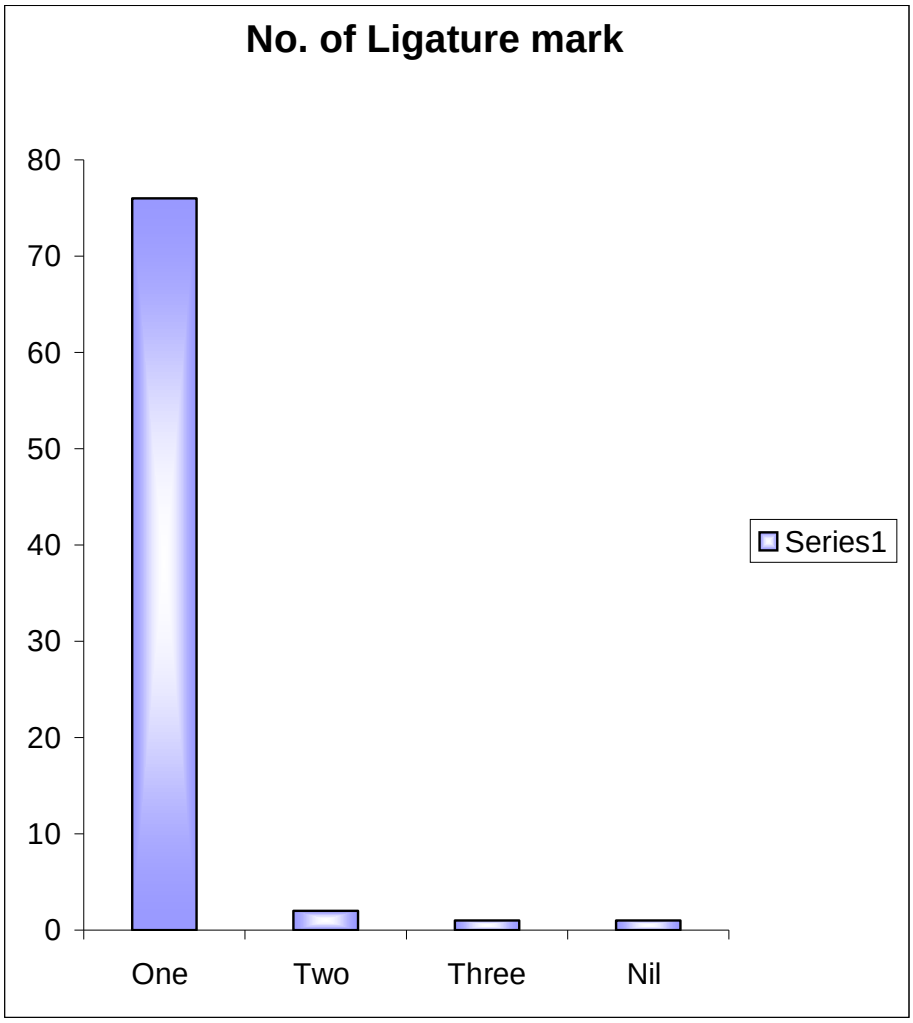

Create PDF files without this message by purchasing novaPDF printer (http://www.novapdf.com)

Distribution among the study population according to the level of ligature mark

TABLE 6 : Level of ligature Mark

Sl. No	Level of ligature mark	No. of victims	%
1	Above the thyroid Cartilage	63	79
2	Overriding the thyroid cartilage	13	16
3	Below the thyroid Cartilage	4	5
	Total	80	100

In the present study it is observed that in 63 cases (79%) the level of the ligature mark was above the thyroid cartilage, below the level of thyroid cartilage in 4 cases (5%) and over riding the thyroid cartilage in 13 cases (16%).

Similar findings were observed in the study conducted by M.P. Sarangi,[25] G.A. Sunil Kumar Sharma, O.P.Murthy,T.D.Dogra[36],Elfawal M.A and O.A. Awad,[21] James L Luke,[6] Betz .P. and Eisenmenger .W.[23],Gary .P. Paparo and Siegel.H..[11]

The reasons for the majority of the mark level being above the thyroid cartilage can be attributed to the complete suspension of the body with posterior knot positioning which causes the material to slide upwards and the factor for the mark to be below the thyroid cartilage is either due to partial suspension or due to a prominent thyroid cartilage.

Create PDF files without this message by purchasing novaPDF printer (http://www.novapdf.com)

Fig 6 : Distribution in the study population according to the level of ligature mark

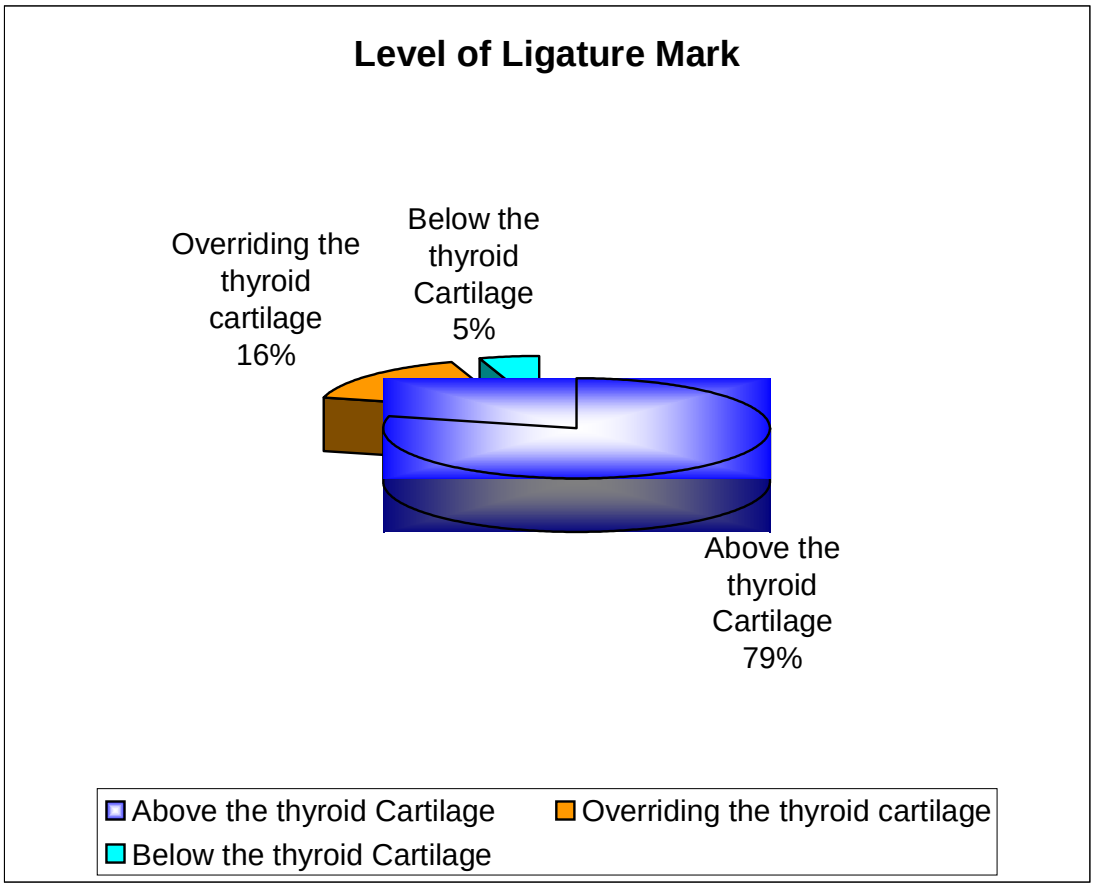

Create PDF files without this message by purchasing novaPDF printer (http://www.novapdf.com)

Distribution in the study population according to the breadth of the ligature mark

TABLE 7 : Breadth of the Ligature Mark

Sl. No	Breadth of ligature mark	Number of victims	%
1	<1 cms	4	5
2	1-2 cms	50	62
3	2-3 cms	23	29
4	> 3 cms	3	4
	Total	80	100

It is observed in the present study population that in 50 cases (63%) the breadth of the mark was 1 to 2 cms, 2 to 3 cms in 23 cases (30%), more than 3 cms in 3 cases (3%) .

Similar results were observed in the studies conducted by GA sunil Kumar Sharma, O.P.Murthy and T.D.Dogra[36],Ryk James and Paul Sillocks,[19] M.P. Sarangi,[25] Elfawal M.A.and O.A. Awad,[21] as the breadth depends solely on the width of the ligature material used and so also the multiplicity of the ligature material.

Create PDF files without this message by purchasing novaPDF printer (http://www.novapdf.com)

Fig 7 : Distribution in the study population according to the breadth of ligature mark

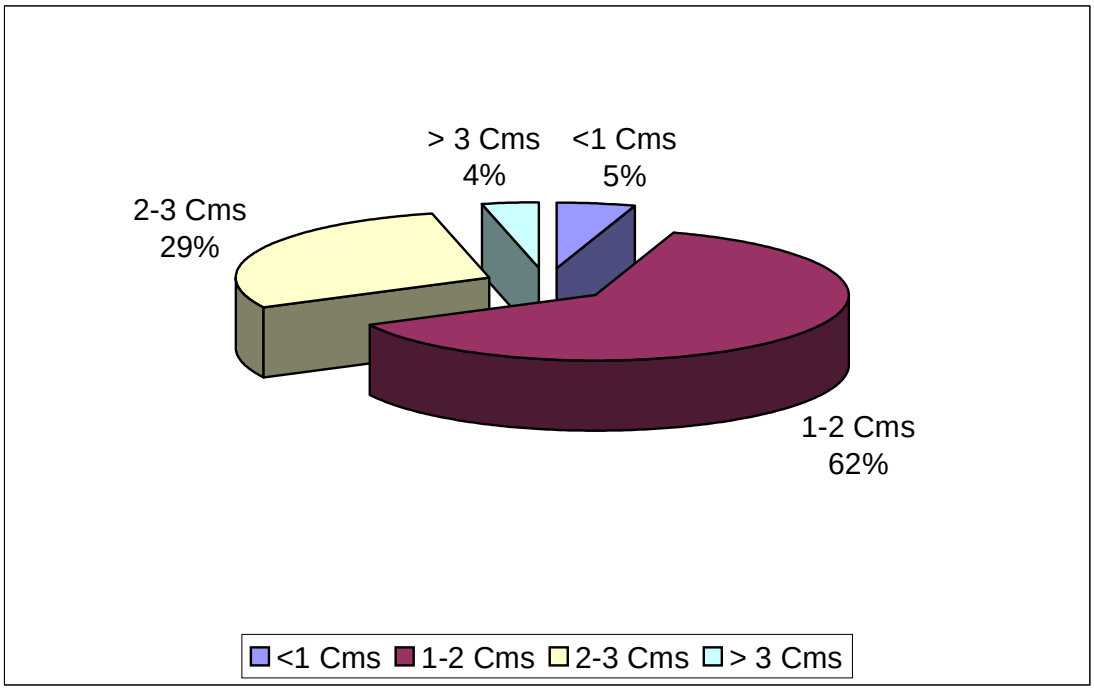

Create PDF files without this message by purchasing novaPDF printer (http://www.novapdf.com)

Distribution in the study population with respect to character of the ligature mark

TABLE 8 : Characteristics of ligature mark

Sl. No	Character of the ligature mark	Number of victims	%
1	Continuous	3	4
2	Interrupted	77	96
3	Faint	17	21
4	Prominent	63	79

In the present study it is noted that 77 cases (95%) had a interrupted ligature mark as compared to the continuous type in 3 cases (3%). The mark is prominent in 63 cases (79%) and faint in 17 cases (21%).

The present study tallys with the findings observed in the studies conducted by M.P. Sarangi,[24] G.A. Sunil Kumar Sharma, O.P.Murthy and T.D.Dogra[36],C.B. Jani and B.D. Gupta,[34] Nikolic Slobadan,Micic Jelena,Atanasijevic Tatjana,Djokic Vesna and Djonic Danijela[39] The reason for the majority being an interrupted ligature mark is complete suspension, of suicidal in manner and prominent mark is due to the type of the material being strong and also increased period of suspension.

Create PDF files without this message by purchasing novaPDF printer (http://www.novapdf.com)

Fig 8 & 9 : Distribution in the study population with respect to character of the ligature mark

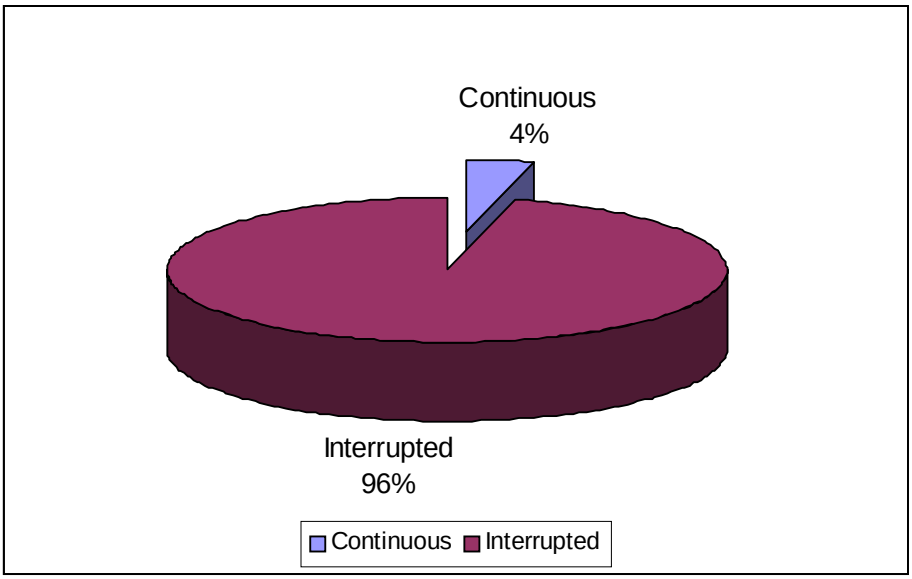

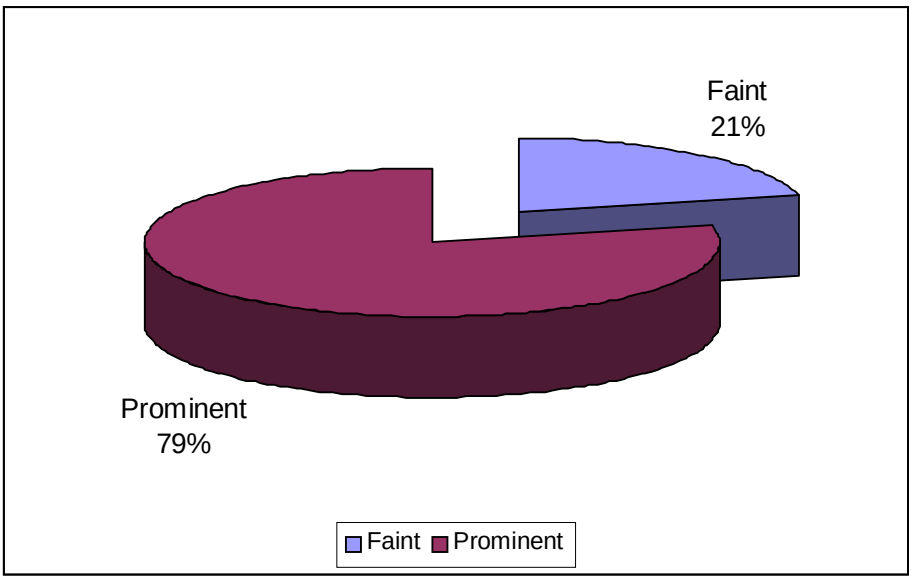

Create PDF files without this message by purchasing novaPDF printer (http://www.novapdf.com)

Distribution among the study population according to the periligature injuries.

TABLE 9 : Periligature Injuries.

Sl. No	Periligature Injuries.	Number of victims	%
	Rope burns as: Periligature injuries		
1	Present	10	10
2	Absent	70	90
	Total	80	100
	Other Periligature injuries		
3	Present	11	14
4	Absent	69	86
	Total	80	100

In the present study 69 cases (86%) did not show any changes around the ligature marks, but in 11 cases (14%) periligature injuries in the form of abrasions, ecchymoses and rope burns (10% of cases) were seen.

The rope burns are due to the heat generated by the friction of the ligature material against the skin due to slippage of the material producing blisters. The above features were observed in the studies conducted by Pradeep Kumar .G.,Manoj Kumar Mohanty,Shanavaz Baipady.[37]

The factors for the production of other periligature injuries being the nail scratch marks inflicted by the struggling victim to free himself, fibres projecting from the material and knot mark bruising.

Create PDF files without this message by purchasing novaPDF printer (http://www.novapdf.com)

Fig 10 & 11 : Distribution in the study population according to the periligature injuries.

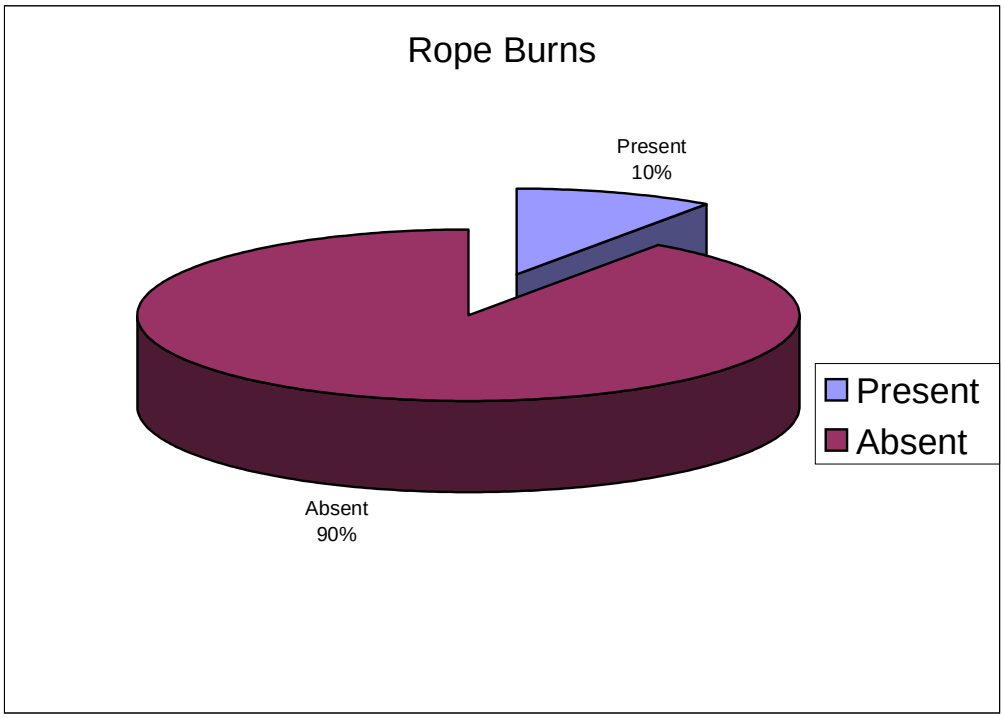

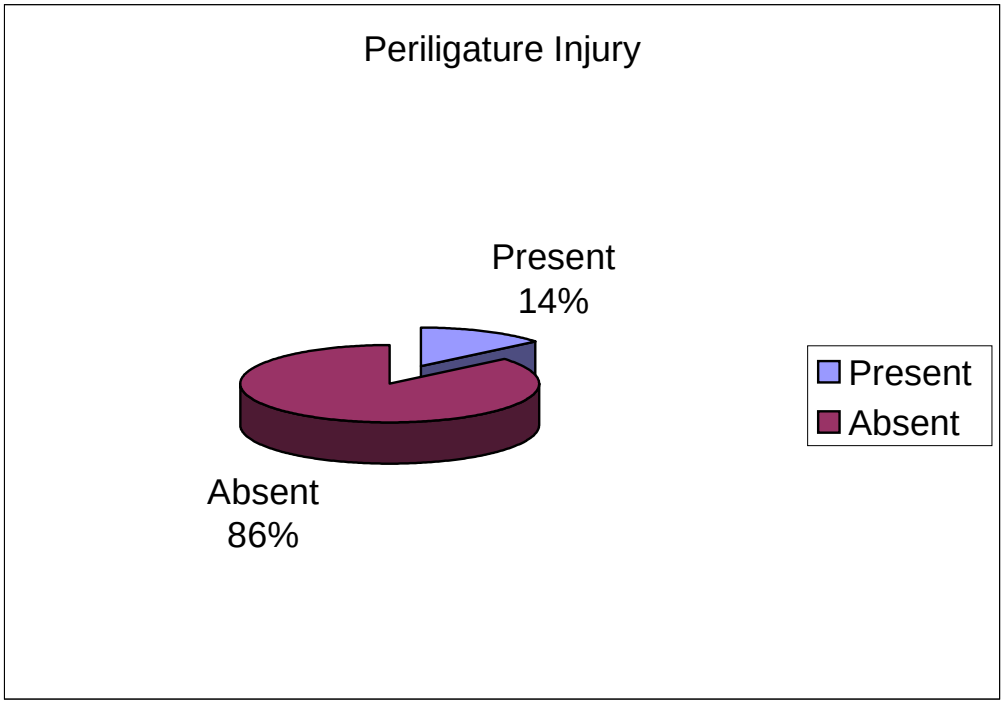

Create PDF files without this message by purchasing novaPDF printer (http://www.novapdf.com)

Distribution in the study population with respect to the texture and parchmentisation of the ligature mark

TABLE 10 : Texture of the ligature mark and Parchmentisation of the ligature mark

Sl. No	Texture of the ligature mark	Number of victims	%
1	Rough	61	76
2	Smooth	19	24
	Total	80	100
	Parchmentisation of the ligature mark		
3	Present	62	77
4	Absent	18	23
	Total	80	100

In the present study it is observed that in 61 cases (76%) the ligature mark was rough, and smooth in 19 cases (24%). Parchmentisation was seen in 62 cases (77%), and absent in 18 cases (23%) Similar results were seen in the studies done by M.P. Sarangi,[25] B.K Sen Gupta,[5] Gary. P. Paparo and Siegel .H.,[11] James L Luke, Reay D.T.,Eisele J.W. and Bonnell H.J.,[13] Andrew Davison and Marshall T.K.[14]

Reasons for the above observations being the form of ligature material and the duration of suspension leading to the parchmentisation in the majority of cases.

Create PDF files without this message by purchasing novaPDF printer (http://www.novapdf.com)

Fig 12 & 13 : Distribution in the study population with respect to the texture and parchmentisation of the ligature mark

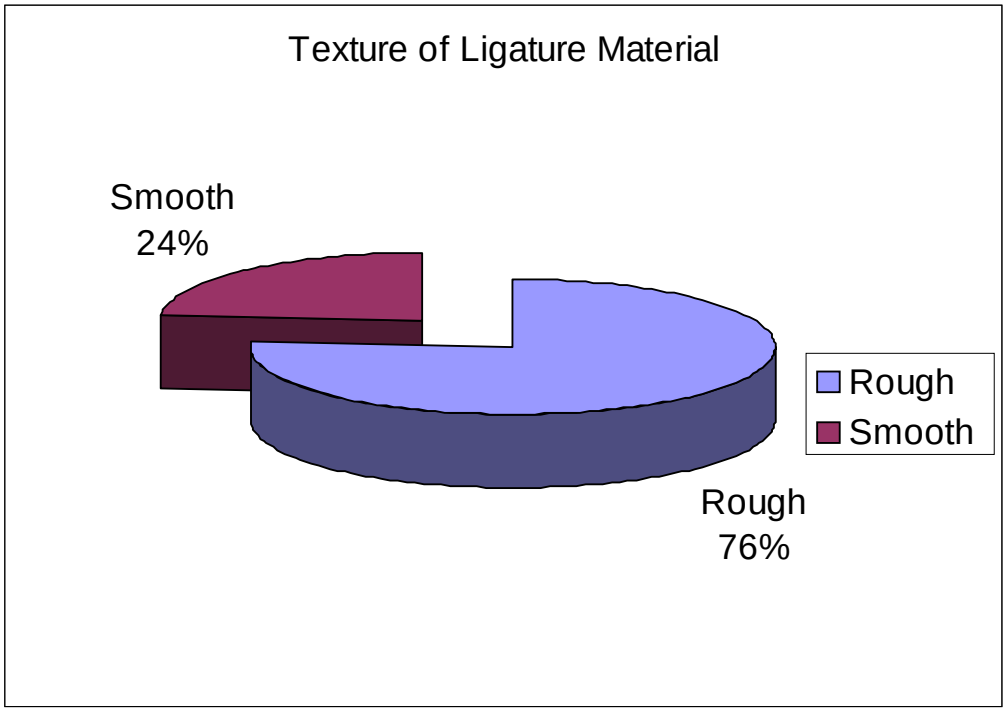

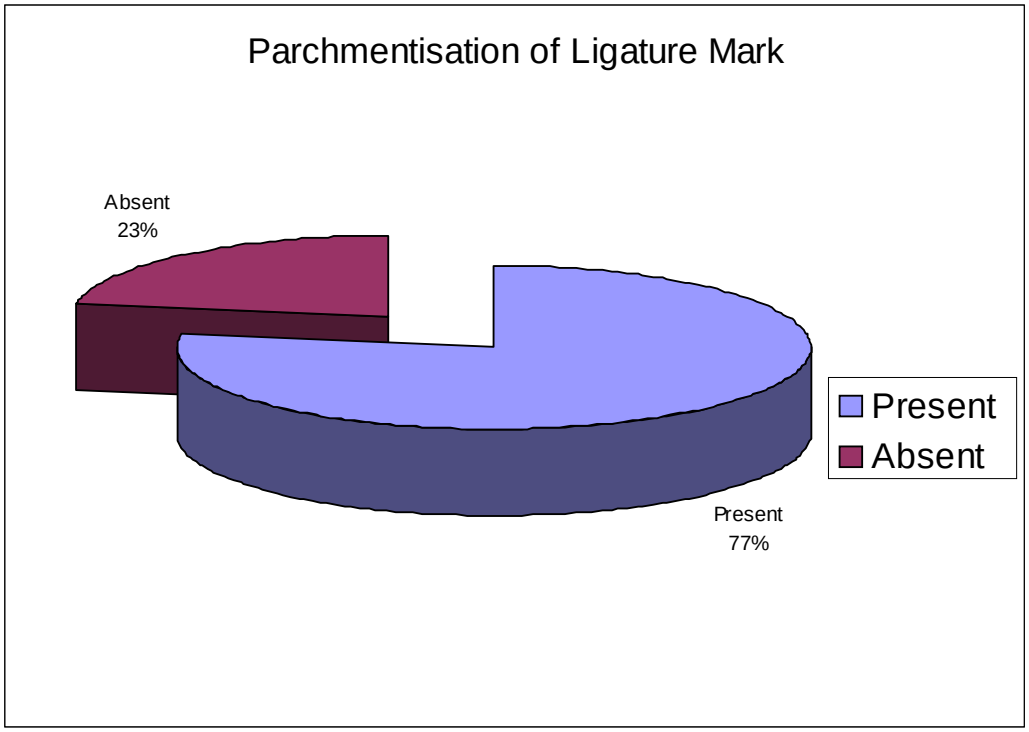

Create PDF files without this message by purchasing novaPDF printer (http://www.novapdf.com)

Distribution in the study population according to the colour of ligature mark

TABLE 11 : Colour of Ligature Mark

Sl. No	Colour of ligature mark	No. of victims	%
1	Pale	14	18
2	Red	19	24
3	Yellowish Brown	21	26
4	Dark Brown	26	32
	Total	80	100

Duration of suspension and the ligature materials used with relation to the colour of the ligature mark.

No. of victims	< 1 hr Pale to red		1- 5hr Yellowish brown to dark brown		> 5 hr Dark brown	
	Soft	Hard	Soft	Hard	Soft	Hard
14	10	4	-	-	-	-
19	9	10	-	-	-	-
21	-	-	15	6	-	-
26	-	-	-	-	10	16

In the present study in 26 cases (32%) the mark was dark brown, in 21 cases (26%) Yellowish brown, in 19 cases (24%) red, and mark was pale in 14 cases (18%). Similar findings were observed in the studies conducted by Andrew Davison and Marshall T.K.[14],G.A. Sunil Kumar Sharma, O.P.Murthy and T.D.Dogra[36],A. Momonchand, Th.Meera Devi and L.Fimate[24],M.A. Elfawal and O.A. Awad.[21]

The reason being the colour of the ligature mark depends on the duration of suspension and the complexion of the person.

Create PDF files without this message by purchasing novaPDF printer (http://www.novapdf.com)

Fig14 : Distribution in the study population according to the colour of the ligature mark

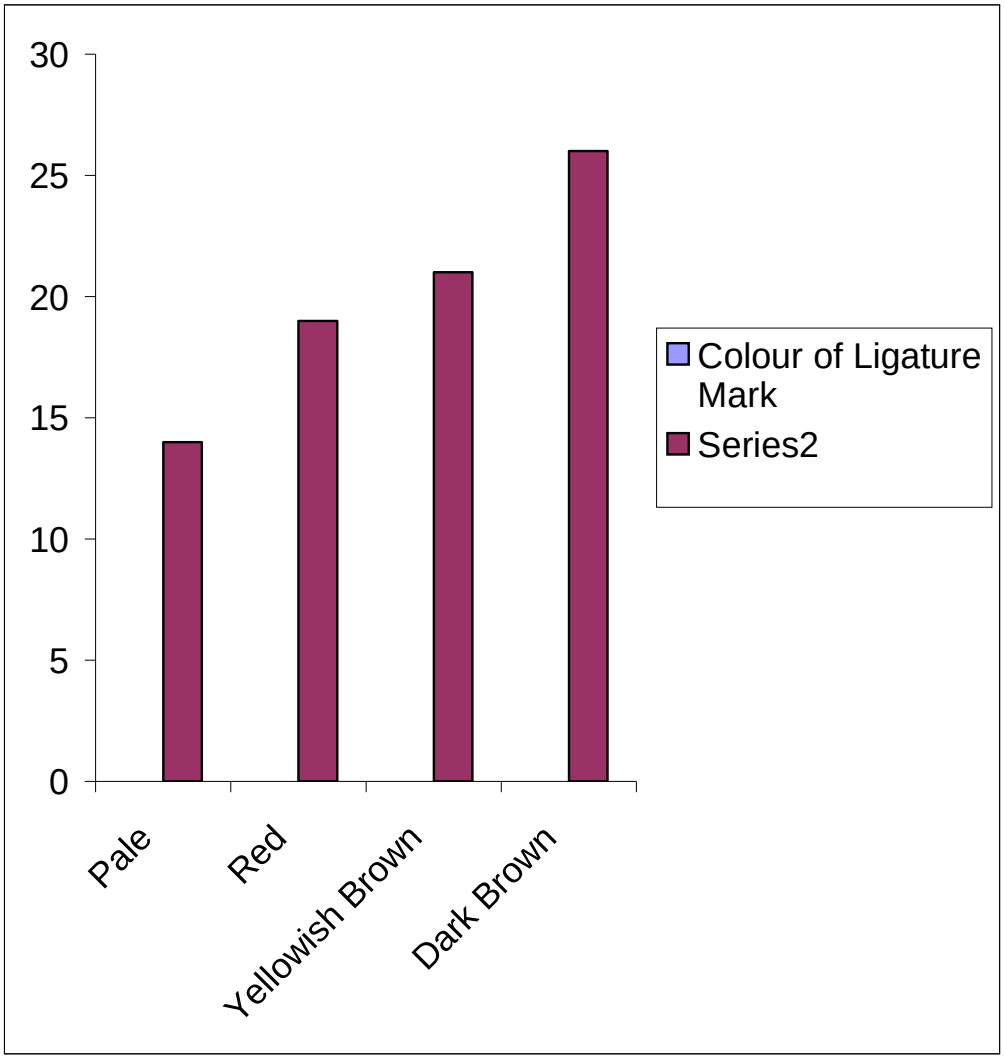

Distribution in the study population with respect to the ligature material used

Create PDF files without this message by purchasing novaPDF printer (http://www.novapdf.com)

TABLE 12 : Ligature Materials Used

Sl. No	Materials used	No. of victims	%
1	Soft	44	55
2	Hard	36	45
	Total	80	100

In the present study in 44 cases (55%) soft ligature material like lungi, duppatta, saree etc. were used and in 36 cases (45%) hard ligature material like nylone rope in 12 cases, electric cord in 3 cases, coir rope in 20 cases, plastic binder in 1 case.

Similar findings were observed in the studies conducted by G.A. Sunil Kumar Sharma,O.P.Murthy and T.D.Dogra[36],Jitendra .K. Balabantaray,[27] B.K. Sen Gupta.[5] Because the suicidee uses readily and easily available ligature material.

It is in contrast to the findings observed by Jonathan P. wyatt, Wyatt P.W.,Squires T.J.,andBusutill.A.[24],Feigin Gerald,[26] the reasons being usage of dogs lead, dressing gown cord, electric cable, suit case webbing, telephone cord, shoes strings, Bath robe belt etc. were used as ligature materials.

Create PDF files without this message by purchasing novaPDF printer (http://www.novapdf.com)

Fig 15 : Distribution in the study population with respect to the ligature materials used.

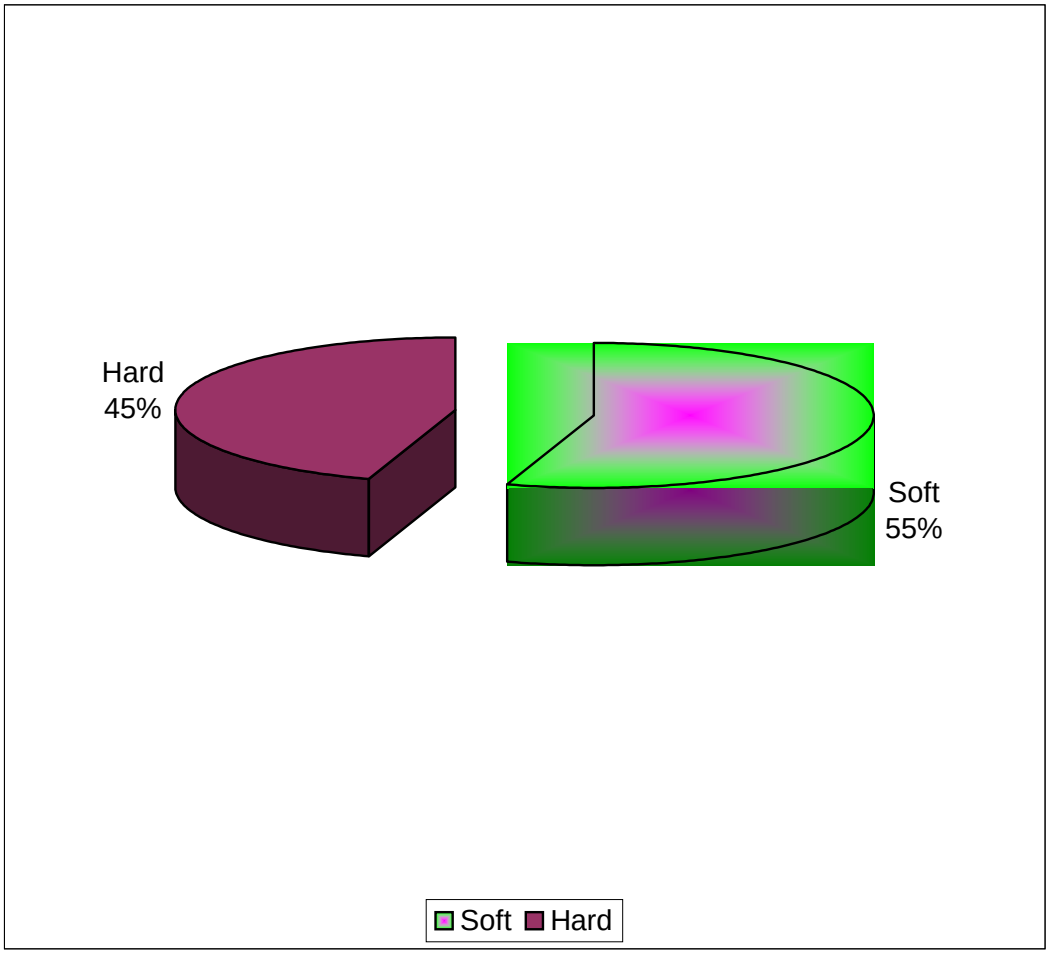

Create PDF files without this message by purchasing novaPDF printer (http://www.novapdf.com)

Distribution in the study population according to the position and type of the knot .

TABLE 13 : Position of the knot

Sl. No	Position of the Knot	No. of victims	%
1	Right occipital	23	28
2	Below the right ear	19	23
3	Left occipital	18	22
4	Occipital	14	18
5	Below the left ear	5	8
6	Below the chin	1	1
7	Others	0	0
	Total	80	100

Table 14 : Type of Knot

Sl. No	Type of knot	No. of victims	%
1	Slipping	44	55
2	Fixed	36	45
	Total	80	100

In the present study it is observed that in 23 cases (28%) the knot was in the right occipital region, in 19 cases (23%) it was below the right ear, in 18 cases (22%) it was in the left occipital region, in 14 cases (18%) occipital knot, in 5 cases (8%) below the left year and in 1 case (1%) below the chin. Right and left and occipital positioning of knot were considered as posterior hangings, knot marks on the left and right anterior aspect of the neck below the ears were considered anterior hangings.

In 44 cases (55%) running noose with a slipping knot were used and fixed knot in 36 cases (45%). Similar findings were observed in the studies conducted by Nicolic Slobodan, Micic Jelena, Atanasijevic Tatjana, Djolic Vesna, Djonic Danijela [39] ,Betz P. and Eisenmenger.w.[23] ,Jorn Simonson,[16] Jitendra K. Balabantaray.[27]

Create PDF files without this message by purchasing novaPDF printer (http://www.novapdf.com)

Fig 16 & 17 : Distribution in the study population according to the position and type of the knot

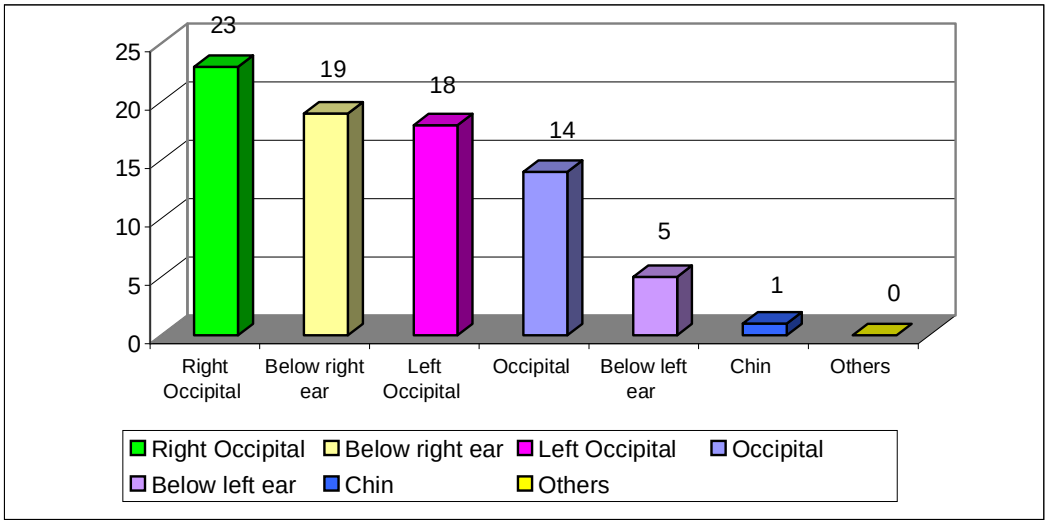

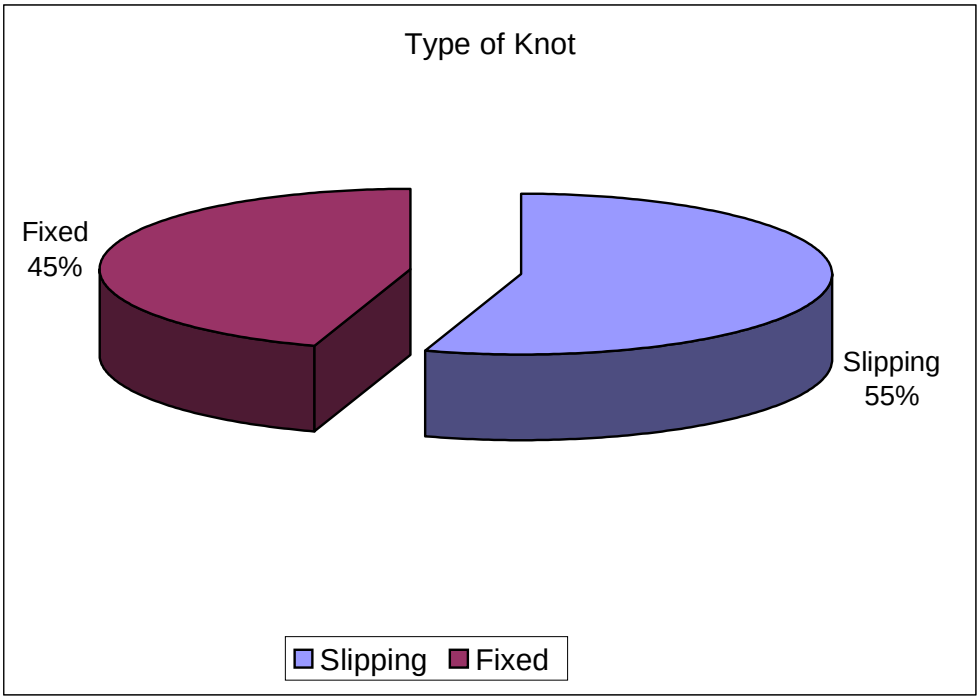

Create PDF files without this message by purchasing novaPDF printer (http://www.novapdf.com)

Distribution in the study population based on effusion of blood into the deep tissues of the neck.

TABLE 15 : Effusion of blood into the deep tissues of the neck

Sl. No	Effusion	No. of victims	%
1	Present	1	1
2	Absent	79	99
	Total	80	100

In the present study population it is observed that in 79 cases (99%) tissues beneath the ligature mark were pale and glistening with effusion of the blood seen in only 1 case. The reason for effusion in this case being the victim after tying the ligature around the neck took a long drop from the branch of a tree.

Similar findings were observed in the studies conducted by M.P. Sarangi,[25] A. Momonchand, Th.Meera Devi and L.Fimate[24],Nikolic Slobodan, Micic Jelena, Atanasijevic Tatjana, Djokic Vesna, Djonic Danijela.[39]

Create PDF files without this message by purchasing novaPDF printer (http://www.novapdf.com)

Fig 18 : Distribution in the study population based on effusion of blood into the deep tissues of the neck

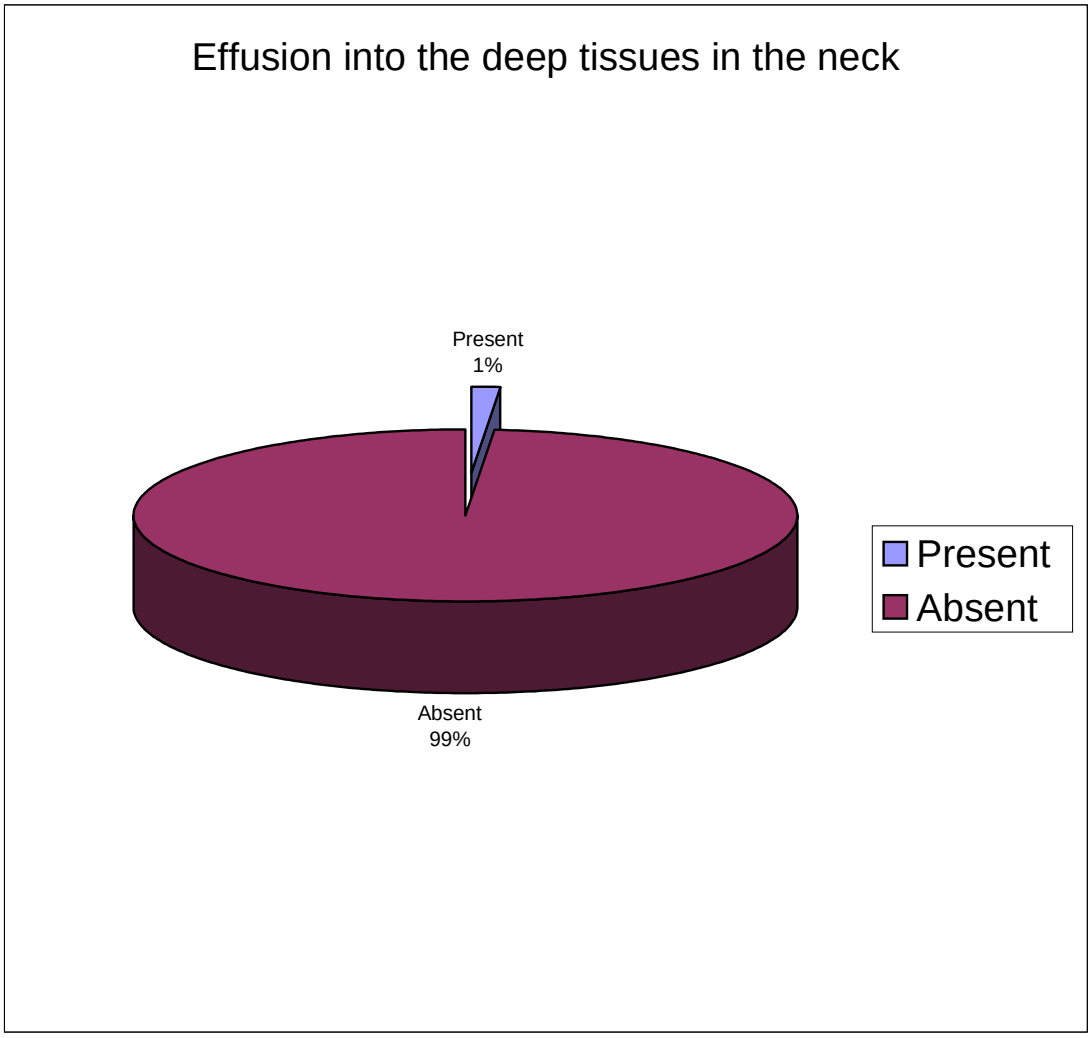

Create PDF files without this message by purchasing novaPDF printer (http://www.novapdf.com)

Distribution in the study population with respect to the fracture of thyroid cartilage and hyoid bone.

TABLE 16 : Fracture of thyroid cartilage

Sl. No	Fracture of thyroid cartilage	No. of victims	%
1	Present	3	4
2	Absent	77	96
	Total	80	100

Table 17 : Fracture of Hyoid bone

Sl. No	Fracture of Hyoid bone	No. of victims	%
1	Present	2	3
2	Absent	78	97
	Total	80	100

In the present study it is observed that in 77 cases (97%) there was no fracture the thyroid cartilage and only in 3 cases (3%) there was a fracture of the superior horn on the left side of the thyroid cartilage. The victims being in their 4th and 5th decades of life. the reasons being complete suspension of the victim, ossification increasing with the age after 30 years, pressure over the horns exerted on to the spine because of greater traction.

Similar findings were observed in the studies done by Nikolic Slobodan, Micic Jelena, Atanasijevic Tatjana,Djokic Vesna, Djonic Danijela.[39],Betz P.and Eisenmenger. S[23],Feigin Gerald,[28] Jitendra Balabantaray.[27] H. Green,James R.A.,Gilbert J.D.,and Byard R.W. [30],Ryk James,[19] Jorn Simonson,[16] Gary. P. Paparo.[11]

In the present study in 78 cases (98%) no fracture was detected and only in 2 cases (2%) showed fracture of the greater cornu on the right side of the hyoid bone.

Create PDF files without this message by purchasing novaPDF printer (http://www.novapdf.com)

The age of the victim more than 60 years. The reason being the fracture increases with the age, seen commonly in typical and complete hanging, in cases of highest level of ligature mark on the back of the neck, increased duration of suspension and with a thin hard ligature material.

Similar findings were observed in the studies done by A. Momonchand, Th.Meera Devi and L.Fimate[22],Ryk James,[17] C.B. Jani and B.D.Guptha,[32] M.P. Sarangi,[23]Betz.P.andEisenmenger.S.[21],NikolicSlobodan,MicicJelena,Atanasijevic Tatjana,Djokic Vesna,Djonic Danijela.[37].,Feigin Gerald,[26] I. Morild,[20] Gary P. Paparo and Siegel.H.[9]

Create PDF files without this message by purchasing novaPDF printer (http://www.novapdf.com)

Fig 19 & 20 : Distribution in the study population with respect to the fracture of thyroid cartilage and hyoid bone.

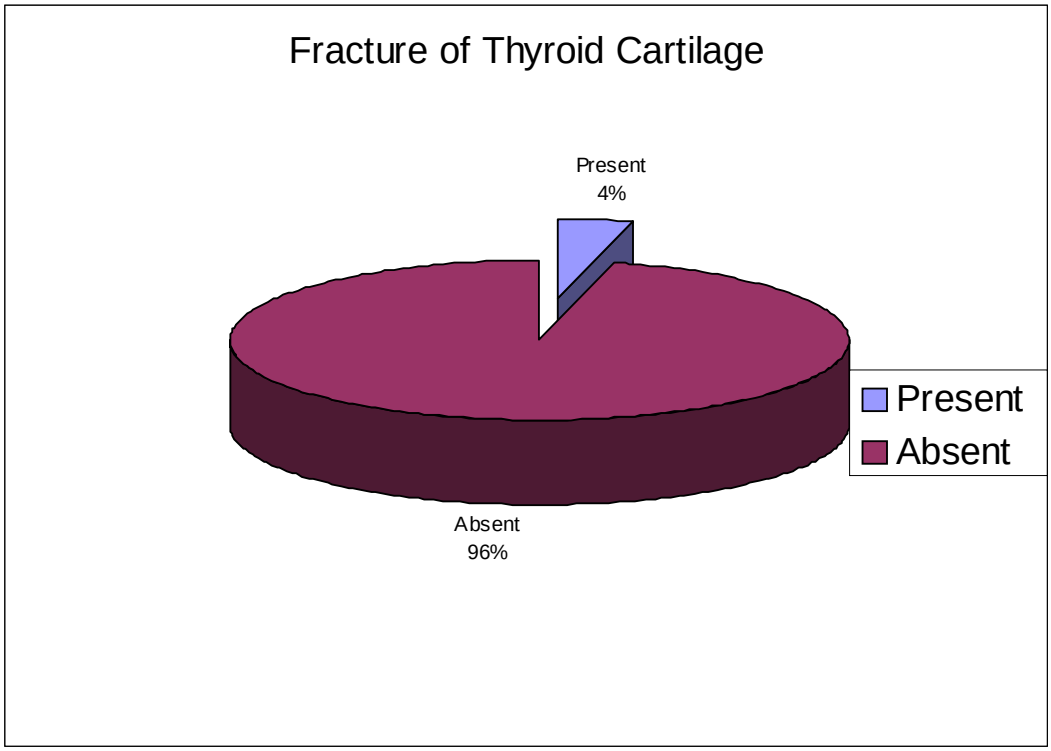

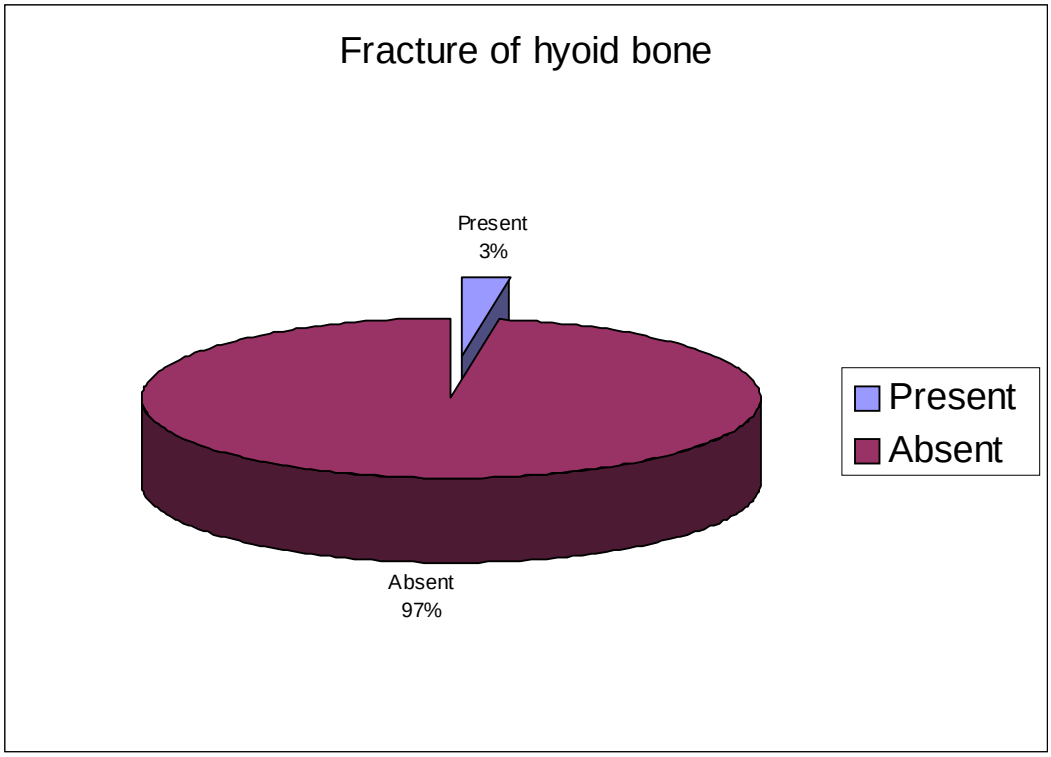

Create PDF files without this message by purchasing novaPDF printer (http://www.novapdf.com)

CONCLUSION

A study on Ligature mark in cases of hanging among autopsies conducted at M.S.Ramaiah Medical college,Bangalore between 2004 and 2005 April concludes as follows:

Characteristic features of the ligature mark observed were:

- Atypical ligature marks with complete hanging outnumbered typical ligature mark with partial hanging.
- Single ligature mark above the level of thyroid cartilage with a breadth of 1to2cms is observed in the maximum number of cases.
- Periligature injuries including rope burns, ecchymoses and abrasions is observed in very few cases.
- Coarse ligature mark with parchmentisation is observed in the majority of the subjects with colour of the ligature mark ranging between yellowish brown to dark brown.
- Soft ligature materials were commonly employed with posterior knot positioning and the type of knot commonly employed being slipping knot.
- Hard and soft ligatures with increased duration of suspension(>5hrs)caused dark brown colour of the ligature mark with parchmentisation. Duration of suspension between 1to5hours with both hard and soft ligatures led to the formation of yellowish brown to dark brown colour of the ligature mark. In cases where the duration of suspension was less than 1hour a pale or faint red colour of the mark was observed.

Create PDF files without this message by purchasing novaPDF printer (http://www.novapdf.com)

- A distinct ligature mark furrow/groove of the width and pattern of the material used is observed in cases where a narrow and tough or hard ligature material is employed . Also in cases of complete hanging prominent ligature mark is observed. With softer and broader ligature materials a less distinct mark is observed. Ligature groove being deepest opposite the side of fixed knot is noted. A slip knot which caused the noose to tighten and squeeze through the full circumference of the neck caused a continuous ligature mark.
- Features of antemortem hanging i.e. dribbling of saliva mark, Le facie sympathique were noticed externally and in some cases the skin with ligature mark was sent for histopathological examination however the results were not conclusive regarding the nature of the ligature mark as antemortem or postmortem .
- All the deaths due to hanging studied were concluded as suicidal in manner based on the history, circumstantial evidence, examination of ligature material, ligature mark characters like a single, interrupted, oblique mark above the level of thyroid cartilage with slipping of the ligature mark, periligature injuries and other internal findings on dissection of the neck tissues .

Create PDF files without this message by purchasing novaPDF printer (http://www.novapdf.com)

SUMMARY

A study on ligature mark in cases of hanging among autopsies conducted at M.S.Ramaiah Medical college, Bangalore between April 2004 and April 2005 was done.

The aims of this study were to study the pattern of ligature marks, study the factors responsible for the formation of ligature marks in relation to the material and correlating the ligature mark with the manner of death.

A sum total of 80cases were selected for this study. Detailed information regarding the deceased and the circumstances of death was collected from the police and relatives by a questionnaire. Standard autopsy technique was employed in all cases.

Maximum number of suicidal hangings occurred in the age group of 20 to 29 years(mean=24.5). Number of hanging deaths in the males were more than the female. Single ligature mark in an interrupted manner with varying degrees of colour changes corresponding to the duration of suspension and ligature material used were observed. Antemortem features of hanging like dribbling of saliva, abrasions, rope burns and ecchymoses around the ligature mark, transverse tears of the intima of carotids, asphyxial signs and Le facie sympathique helped in ascertaining the cause, nature and manner of death. Microscopic findings of ligature site skin after the histopathological examination were opined as keratinized epidermis, dermis showing focal aggregation of mononuclear cell infiltration including lymphocytes and congested vessels in the deeper dermis with melanin incontinence with an impression stating the antemortem ligature site reaction.

In a few cases the victims had resorted to committing suicide by hanging after consuming poison (Attempted dual methods).

Create PDF files without this message by purchasing novaPDF printer (http://www.novapdf.com)

LIMITATIONS OF THE STUDY

1. Study confined to a particular area.

2. Information regarding the deceased is based only on the history provided by police, relatives, panchanama, photograph of the scene of occurrence.

Create PDF files without this message by purchasing novaPDF printer (http://www.novapdf.com)

RECOMMENDATIONS

- In the present study, using the histopathological examination of the skin over the ligature mark to decide the antemortem or postmortem nature of the ligature mark was not of conclusive value. Hence this gives wide scope for other methods like enzyme histochemistry and other biochemical markers which could play a vital role in deciding the nature of the ligature mark as antemortem or postmortem.
- In cases of a faint or absent ligature mark using a cellophane tape over the area of the ligature mark on the neck and analyzing it under a comparative microscope with the material could collaborate with the ligature material.

From the medico legal point of view, it is recommended that in cases of deaths due to hanging the following protocol is necessary:

- Photograph of the scene of occurrence should include point of suspension.
- In fatal cases not to disturb the ligature material and release only the suspension point.
- To always bring the material along with the body for correlation with the mark.
- Radiograph of the neck plays a vital role to appreciate the fractures of hyoid bone and thyroid cartilage.
- If necessary to visit the scene of occurrence.

Create PDF files without this message by purchasing novaPDF printer (http://www.novapdf.com)

BIBLIOGRAPHY

1. **Parikh C.K.** "Parikh's textbook of medical jurisprudence, Forensic Medicine and Toxicology for classrooms and courtrooms". 6th edition,CBS publishers and distributors,New Delhi;1999: 3.33-4.10.
2. **Gray's.** "Text Book of Human Anatomy." 33rd Edition, The bath press, ELBS; 1965: 1248-1260.
3. **Otto Sapphire**. "Autopsy Diagnosis and Technique". 4th Edition, Illinois : Hoeber Harper.
4. **Sen Gupta B.K**. "Studies on 101 cases of Death due to Hanging". Journal of Indian Medical Academy, 1965; 45(3):135-139.
5. **Luke J.L.** "Asphyxial Deaths by Hanging in NewYork City,1964-1965." Journal of Forensic Science 1967;12(3):359-369.
6. **Polson C.J. and Gee D. J.** "The essentials of forensic medicine". 3rd edition, Oxford: Pergamon Press,1973: 370-339.
7. **Narayan Reddy K.S.** "Fracture of the Hyoid bone." Journal of the Indian academy of Forensic Medicine 1978; (1) : 7-15.
8. **Bowen D.A.LL.** "Hanging – A review". Forensic Science International 1982; 20 : 247-249.
9. **J.K. MASON.** "Forensic Medicine for lawyers." 2nd edition, London Butterworths Publishers;1983: 130-132.
10. **Paparo G.P. and Siegel H.** "Neck markings and fractures in suicidal hangings." Forensic Science International 1984; 24:27-35.
11. **Mant A. K.** "Taylor's Principles and practice of Medical Jurisprudence." 13th Edition, Churchill Livingstone Edinburgh; 1984: 303-319.

Create PDF files without this message by purchasing novaPDF printer (http://www.novapdf.com)

12. **Luke J.L., Reay D.T., Eisele J.W. and Bonnell H.J.** "Correlation of Circumstances with Pathological Findings in Asphyxial Deaths by Hanging: A Prospective Study of 61 cases from Seattle, WA". Journal of Forensic Sciences 1985; 30(4): 1140–1147.
13. **Davison A and Marshall T.K.** "Hanging in Northern Ireland-A Survey." Medicine Science and Law, 1986; 26(1): 23–28.
14. **Jeanette Guarner.** "Suicide by Hanging" a Review of 56 cases, The American journal of Forensic Medicine and Pathology, 1987; 8(1): 23-25.
15. **Simonsen J.** "Patho-anatomic findings in neck structures in asphyxiation due to hanging: a survey of 80 cases". Forensic Science International 1988; 38:83-91.
16. **Cooke C.T, Cadden G.A & Hilton J.M.N.** "Unusual Hanging Deaths." The American Journal of Forensic Medicine & Pathology, 1988; 9(4): 277-282.
17. **Cox H.W.V. Bernard Knight, V.B. Salai, V.S. Sinha, M.L. Singhal.** "Medical Jurisprudence and Toxicology." 6th Edition,The law book company (p) Ltd; 1990 : 249-269.
18. **Ryk James and Paul Silcocks.** "Suicidal Hanging in Cardiff-A 15 Year Retrospective Study." Forensic Science International 1992; 56:167-175.
19. **Moore.L. & Byard R.W.** "Pathological findings in hanging and wedging deaths in infants and children." The American Journal of Forensic Medicine & Pathology, 1993; 14(4): 296-302.
20. **Elfawal M.A. and Awad O.A.** "Deaths from Hanging in the Eastern province of Saudi Arabia." Medicine Science and Law, 1994;34(4):307–312.
21. **Morild I.** "Fractures of neck structures in suicidal hanging". Medicine Science and Law. 1996; 36(1): 80-84.

Create PDF files without this message by purchasing novaPDF printer (http://www.novapdf.com)

22. **Betz P. and Eisenmenger W.** "Frequency of throat-skeleton fractures in hanging". The American Journal of Forensic Medicine & Pathology 1996; 17(3): 191-193.
23. **A.Momanchand, Th. Meera Devi, L.Fimate.** "Violent asphyxial deaths in Imphal." Journal of Forensic Medicine and Toxicology, 1998; 15(1):60-64.
24. **Sarangi M.P.** "Ligature Mark/s- In Forensic Pathologist's Perspective." Journal of Forensic Medicine and Toxicology 1998; 15(1): 99-102.
25. **Wyatt JP, Wyatt PW, Squires TJ and Busuttil A.** "Hanging Deaths in Children." The American Journal of Forensic Medicine and Pathology 1998; 19(4): 343-346.
26. **Balabantaray J.K.** "Findings in Neck Structures in Asphyxiation due to Hanging." Journal of the Indian Academy of Forensic Medicine, 1998;20(4): 82-84.
27. **Feigin G.** "Frequency of neck organ fractures in hanging". American Journal of Forensic Medicine & Pathology 1999; 20(2): 128-130.
28. **Subrahmanyam B.V.** "Modi's Medical Jurisprudence and Toxicology." 22nd edition Butterworths India, NewDelhi ;1999: 251-272.
29. **Green H., James R. A., Gilbert J. D. and Byard R. W.** "Fractures of the hyoid bone and laryngeal cartilages in suicidal hanging". Journal of Clinical Forensic Medicine 2000; 7(3): 123-126.
30. **Apurba Nandy.** "Principles of Forensic Medicine", 2nd Edition, New central Book agency (P) Ltd; 2000 : 315-321.
31. **Dixit P.G, Mohite P.M and Ambade V.N.** "Study of histopathological changes in thyroid, salivary gland and lymph nodes in hanging." Journal of Forensic Medicine and Toxicology, 2001; 18(2):1-4.
32. **Varghese.P.S.** "Frequency of Fracture of hyoid bone and Thyroid cartilage in cases of Hanging" unpublished MD Dissertation submitted to the RGUHS, 2001. Personal communication.

Create PDF files without this message by purchasing novaPDF printer (http://www.novapdf.com)

33. **Jani C.B. and Gupta B.D**. "An autopsy study of parameters influencing injury to osteocartilaginous structures of neck in hanging". International Journal of Medical Toxicology & Legal Medicine 2002; 5(1): 4-7.
34. **Vij Krishan.** "Textbook of Forensic Medicine and Toxicology." 2nd edition B.I.Churchill Livingstone, New Delhi; 2002: 242-263.
35. **A. Sunil Kumar sharma, O.P. Murthy, T.D.Dogra.** "Study of ligature marks in asphyxial deaths of hanging and strangulation". International Journal of Medical Toxicology and Legal Medicine 2002; 4(2):21-24.
36. **Pradeep Kumar G. Manoj Kumar Mohanty. Shanavaz Baipady.** "Rope Burns :A feature of Antemortem Hanging". Journal of Karnataka Medicolegal Society, 2002 ;11 (2): 25-26.
37. **Manoj Kumar Mohanty, Prateek Rastogi, Virendra Kumar, Shanavaz Manipady.** "Periligature injuries in Hanging." Journal of Clinical Forensic Medicine 2003;10(4): 255-258.
38. **Nikolic Slobodan, Micic Jelena, Atanasijevic Tatjana, Djokic Vesna, Djonic Danijela.** "Analysis of Neck Injuries in Hanging [Case Report]" The American Journal of Forensic Medicine and Pathology 2003; 24(2): 179-182.
39. **Bernard knight,"**Knight's Forensic Pathology**"** III Edition; 2004(15): 383 – 389.
40. **V.V. Pillay.** "Textbook of Forensic Medicine." 14th Edition 2004; (13): 223 – 228.
41. **J.K. Mason and B. N. Purdue**. "The Pathology of Trauma." III Edition; 2004 (15) : 244-248.
42. **Deepak H.D.** "Pattern of Hyoid Bone Fractures in Deaths due to Pressure on the neck" unpublished MD Dissertation submitted to the RGUHS, 2005. Personal communication.

Create PDF files without this message by purchasing novaPDF printer (http://www.novapdf.com)

ANNEXURE I

QUESTIONNAIRE ON

STUDY OF LIGATURE MARK IN CASES OF HANGING

Information furnished by the Police /Relatives :

Name : Place of Death : Residence / Work place / Outside

Age : Date and place of death :

Sex :

Partial / Complete. Height of Suspension :

Hanging Type:

Typical / Atypical. Duration of Suspension :

Ligature Mark :

a. Number of ligature Marks : One / Two / Three / Nil.

b. Level of Ligature Mark : Above the thyroid cartilage.

Overriding thyroid cartilage.

Below the thyroid cartilage .

c. Direction of the Ligature Mark :

d. Length and Breath :

e. Relation to local landmark :

f. Continuous or interrupted

g. Impression of Ligature Mark : Faint / Prominent .

h. Slipping of Ligature Mark : Present / Absent .

i. Rope burns : Present / Absent .

j. Abrasion, contusion, nail marks

Or other periligature injuries : Present / Absent .

Create PDF files without this message by purchasing novaPDF printer (http://www.novapdf.com)

k. Texture of ligature Mark : Rough / Smooth / dry.

l. Parchmentisation : Present / Absent .

m. Colour of Ligature Mark : Pale / Reddish / Yellowish Brown / Dark Brown .

n. Extravasation of Blood at the Margin : Present / Absent.

o. P.M. Staining on the upper border of Ligature Mark : Present / Absent.

Ligature Materials : Saree / Dupatta / Towel / Lungi / Rope / Others.

Length of Ligature Materials :

Position of the Knot : Occipital / Rt occipital / Lt occipital / Chin /Below right ear / Below left ear, Others .

Type of Knot : Slipping / Fixed / Unknown .

External Appearances :

a. Cyanosis : Present / Absent .

b. Petechial Haemorrhages : Present / Absent .

c. Sub – conjunctival Haemorrhages : Present / Absent .

d. Dribbling of Saliva Mark : Present / Absent .

e. Discharge of Semen / Faeces : Present / Absent .

f. Tongue bitten / Protruded : Present / Absent .

g. Clenching of Fist : : Present / Absent .

Create PDF files without this message by purchasing novaPDF printer (http://www.novapdf.com)

Internal Injuries :

Tissue underneath ligature Mark :

a. Pale : Yes / No .

b. Glistening white : Yes / No .

c. Contusion of deep tissues in neck : Present / Absent.

Thyroid cartilage : Fractured / Intact.

Other Laryngeal cartilages : Fractured / Intact .

Hyoid bone : Fractured / Intact .

Cause of Death : Hanging / Others .

Manner of Death : Suicidal / Accidental / Undecided.

Create PDF files without this message by purchasing novaPDF printer (http://www.novapdf.com)

ANNEXURE II

M.S. RAMAIAH HOSPITALS

(MSRMTH/MSRIC/MSRINU)

M. S. R. Nagar, M.S.R.I.T.Post, Bangalore –560054.
Tel: 91-80-3608888/3608961/3606524/3606545; Fax:91-80-3601924;
E-mail: msrhospitals @ vsln.com.

Name of Patient: S. Suryanarayan Date: 4/3/05 Patient .No: PM.No.110/05 dt.23/2/05
Treating Doctor: Age: 48 Years HPE.MLC.18/05
Dept.: Forensic Medicine Sex: Male Ward

Specimen received on: 2/3/05
Nature of Specimen: Skin.

MACROSCOPY: Specimen of skin covered soft tissue bit measuring 1.5x1cms. Ligature mark seen over the external surface. Cut section – Grey white.
A- Normal, B- from ligature mark

MICROSCOPY: Sections A from the normal area shows skin with epidermis. The dermis shows foci of mononuclear cell infiltration.
Sections B shows skin with dermis and epidermis. The epidermis is lined by stratified squamous epithelium with focal ulceration. Subepithelium shows disruption of the fibrocollagenous tissue, edema and congested blood vessels.

IMPRESSION: Skin – Features are consistent with ligature site reaction.

4/3/05

PATHOLOGIST.

for PROF. & HEAD, DEPT. OF PATHOLOGY
M.S. Ramaiah Medical College
BANGALORE-560 054

Create PDF files without this message by purchasing novaPDF printer (http://www.novapdf.com)